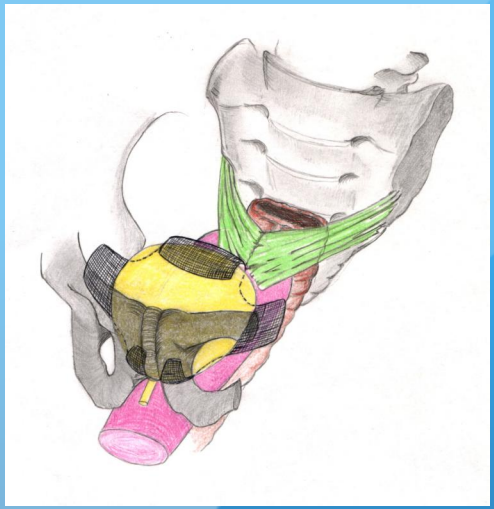

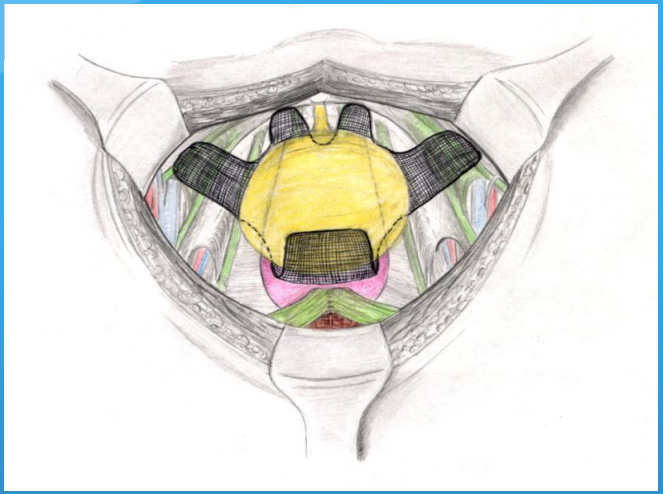

UNFIXED ULTRALIGHT POLYPROPYLENE MESH FOR ANTERIOR VAGINAL WALL PROLAPSE : TOWARDS A SOLUTION TO CONTRACTION OF MESH ? A VERY LONG TERM FOLLOW-UP STUDY OF A COHORT OF 90 PATIENTS

A. Mansoor, A. Zangarelli, S. Curinier, S. Campagne-loiseau, B. Rabischong

University Hospital

Clermont Ferrand

France

Pelvic Organ Prolapse

- 40% of women aged 50-79 years
  - Some degree of POP
- Anterior vaginal wall prolapse most common
  - Represents >80% of all POP surgery
- Recurrence rate of traditionnal anterior colporraphy : 40-60%
- Mesh augmentation surgery improve anatomical results : 89-97% succes rate
- Mesh related complications
  - Vaginal exposition : 3-16%
  - Visceral erosion, infection,
  - MESH CONTRACTION : chronic pain and dyspareunia

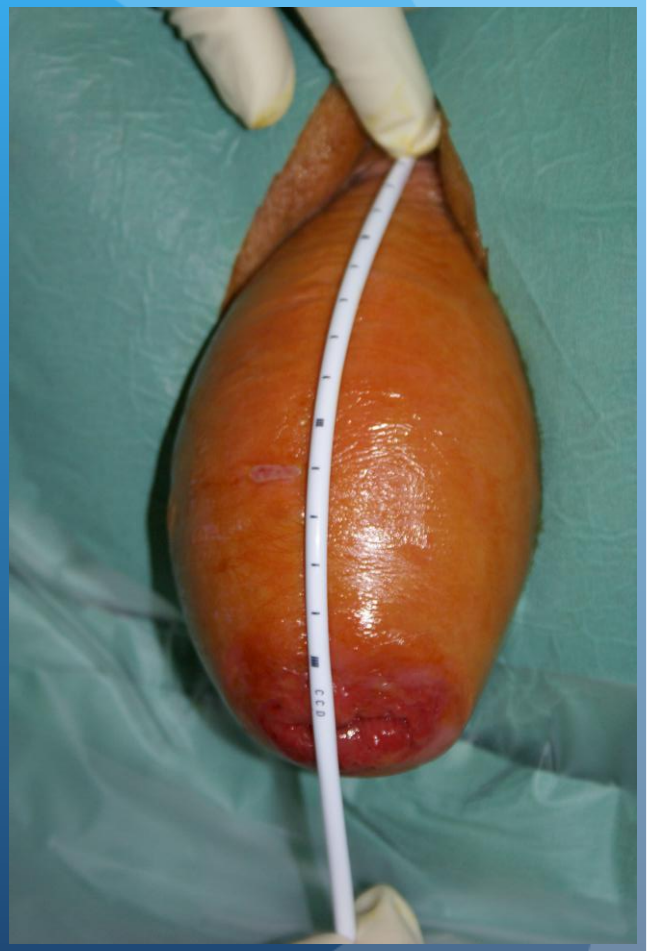

Unfixed meshes : a different philosophy

- Fixed meshes TVM, trans-obturator arms or sacro-spinous ligament fixation
  - The mesh corrects the POP, replace vaginal support and ligaments
    - The mesh supports the entire abdominal pressure permanently
    - May explain the behavior of mesh with fixed arms
    - Intense inflammatory reaction along arms which are under tension
    - May explain pelvic pain and dyspaneunia

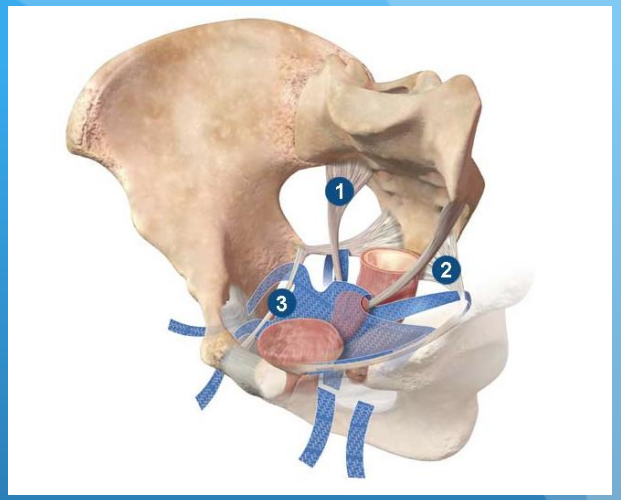

- Unfixed meshes
  - Role of mesh
    - Does not correct the prolapse but re-inforce fascia and ligaments
    - Necessity of optimal anatomic correction of prolapse
    - Solid apical fixation :Mac Call or sacro-spinous vault fixation; Anterior and posterior repair
  - Mesh can contract freely
  - May explain the absence of pain and dyspareunia

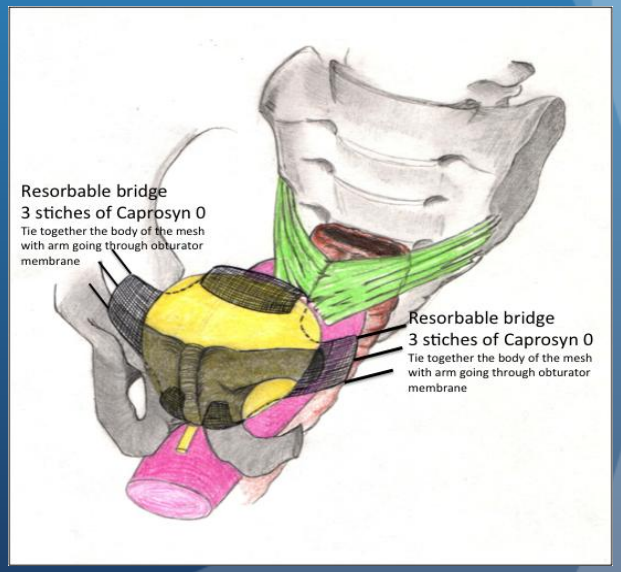

Can clinical consequence of mesh contraction be prevented ?

Mesh contraction: fixed or unfixed meshes

Unfixed mesh

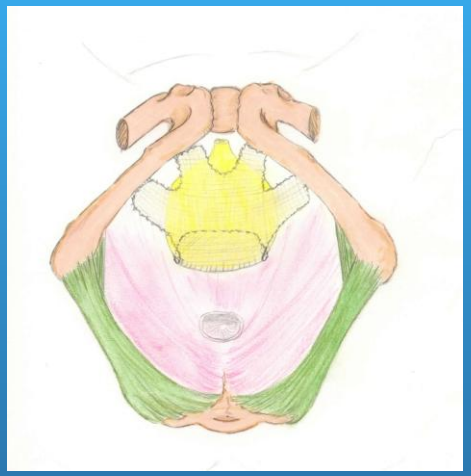

Unfixed mesh at the time of surgery

- 40%

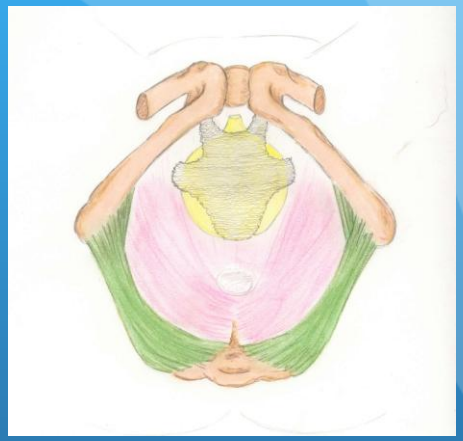

After contraction

* No rigidity
* No clinical result of contraction

Fixed arms

Ex : TVM

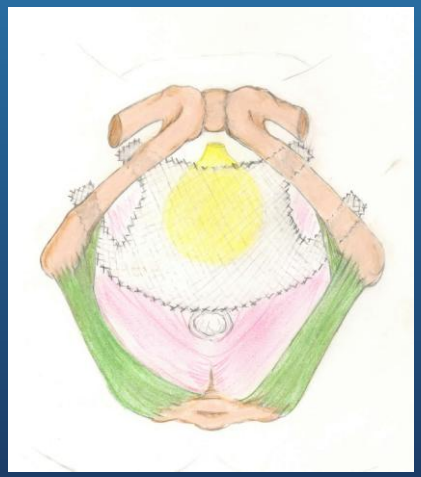

- 40%

↗ Pain on arms
Rigidity of mesh

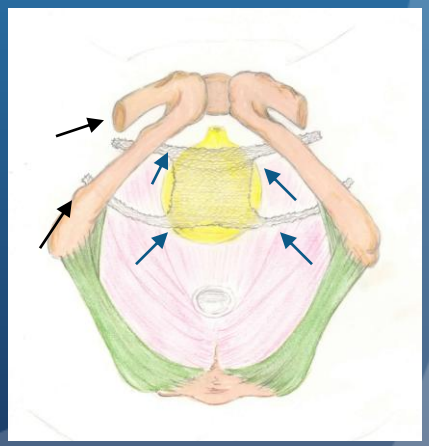

Schémas de Nathalie Pandolfo

CONTRACTION OF MESH : Repair of fascial defect :

- E. Nohuz, B. Jacquetin 2014
  - Polypropylene : 29%
  - With Seprafilm : 19%
  - With Hyalobarrier : 17%

Figure 1: Anterior abdominal wall hernia induction and antiadhesion barriers application

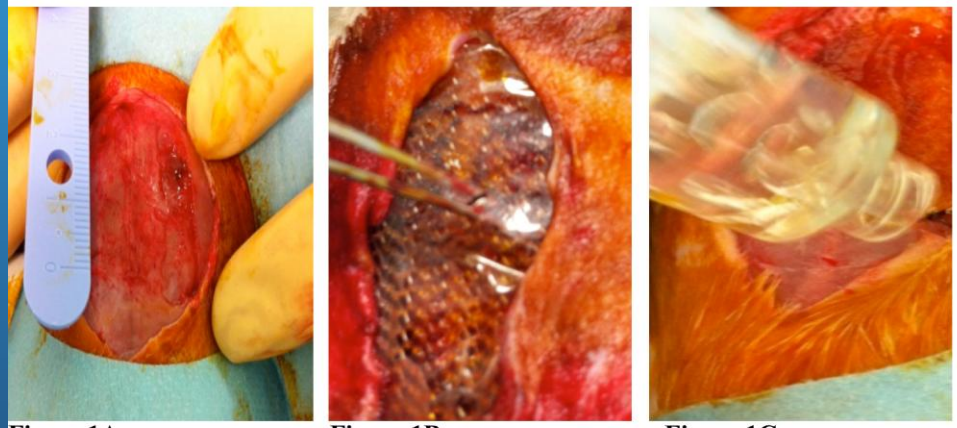

Figyre 1A **Figure 1B** **Figure 1C**

Figure 1A: Anterior abdominal wall hernia induction

Figure 1B: Seprafilm® application

Figure 1C: Hyalobarrier®-gel application

Int Urogynecol J. 2014 Aug;25(8):1081-7.

Contraction of mesh
Animal studies

- Unfixed mesh contracts very little
  - Boukerrou M, Cosson M, 2007
    - Mesh 60 X 40 mm
      - Contraction rate
        - Prolène : 1 mm (1,7%)
        - Prolène soft : 4 mm (6,6%)
        - Mersuture : 3 mm (5%)
        - Vicryl : 6 mm (10%)
        - Vypro : 11 mm (18%)



Fig. 1. Placement of prostheses without fixation: tension-free.

Study of the biomechanical properties of synthetic mesh in vivo
European Journal of Obstetrics and Gynecol 134 (2007)

- Unfixed mesh contracts very little
  - L. Zogbi (2009)
    - Mesh put on abdominal fascia, fixed on 4 corners, NO parietal defect
    - Contraction rate
      - Marlex : Heavy weight PP with pore size 0.6mm : 2,76 %
      - Parietene : Low weight PP with pore size 1.5mm : 4,5%

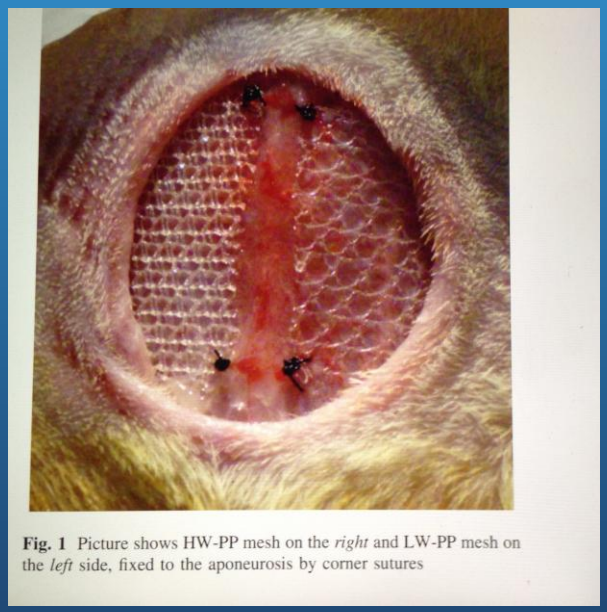

Fig. 1 Picture shows HW-PP mesh on the *right* and LW-PP mesh on the *left* side, fixed to the aponeurosis by corner sutures

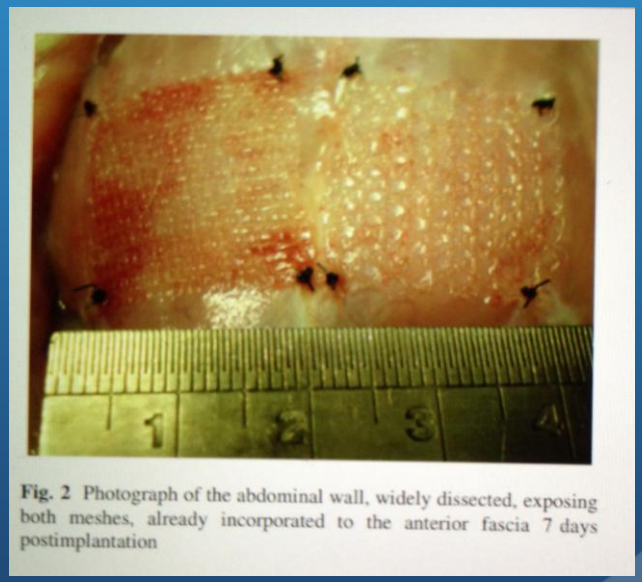

Fig. 2 Photograph of the abdominal wall, widely dissected, exposing both meshes, already incorporated to the anterior fascia 7 days postimplantation

Comparative study of shrinkage, inflammatory response and fibroplasia in heavy weight and light weight meshes. Hernia (2013) 17

Unfixed anterior Prolene° mesh

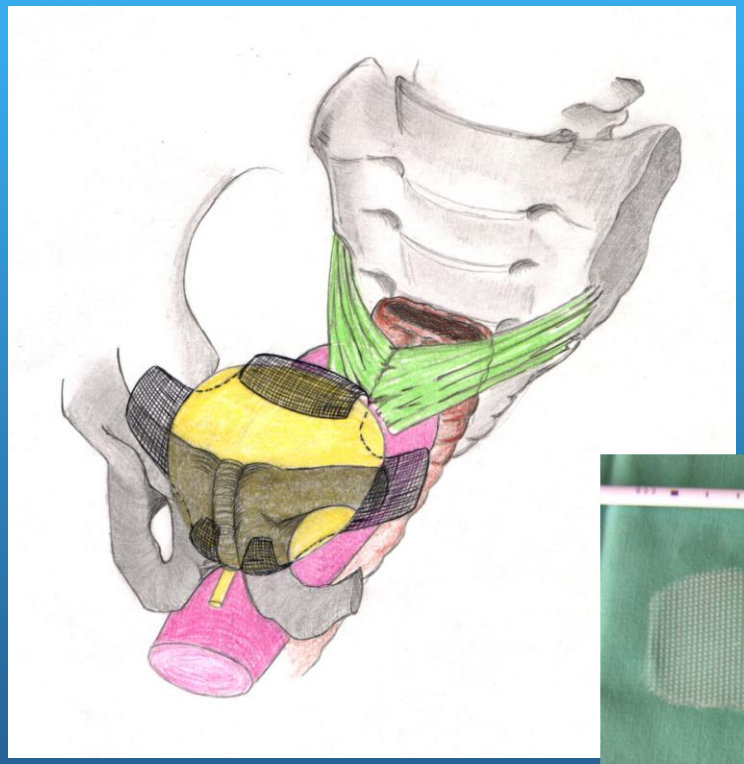

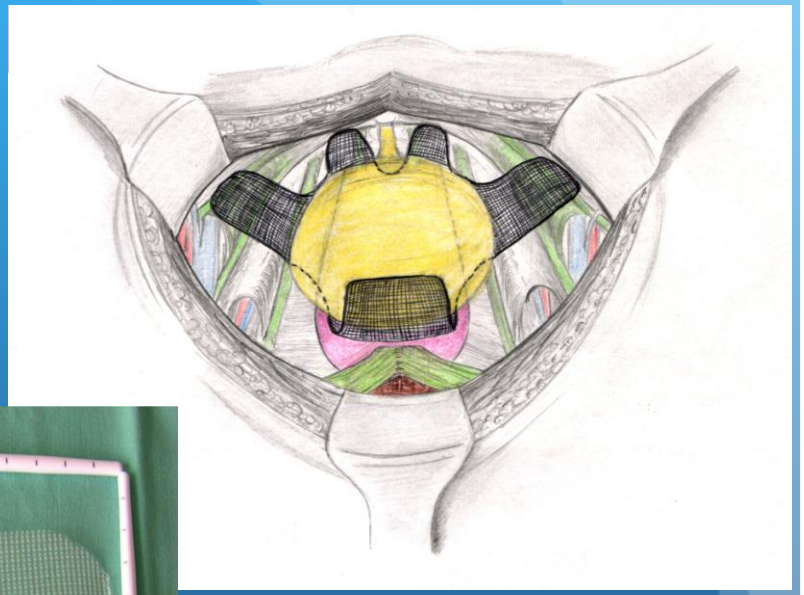

Ultrasonography of unfixed Polypropylene mesh

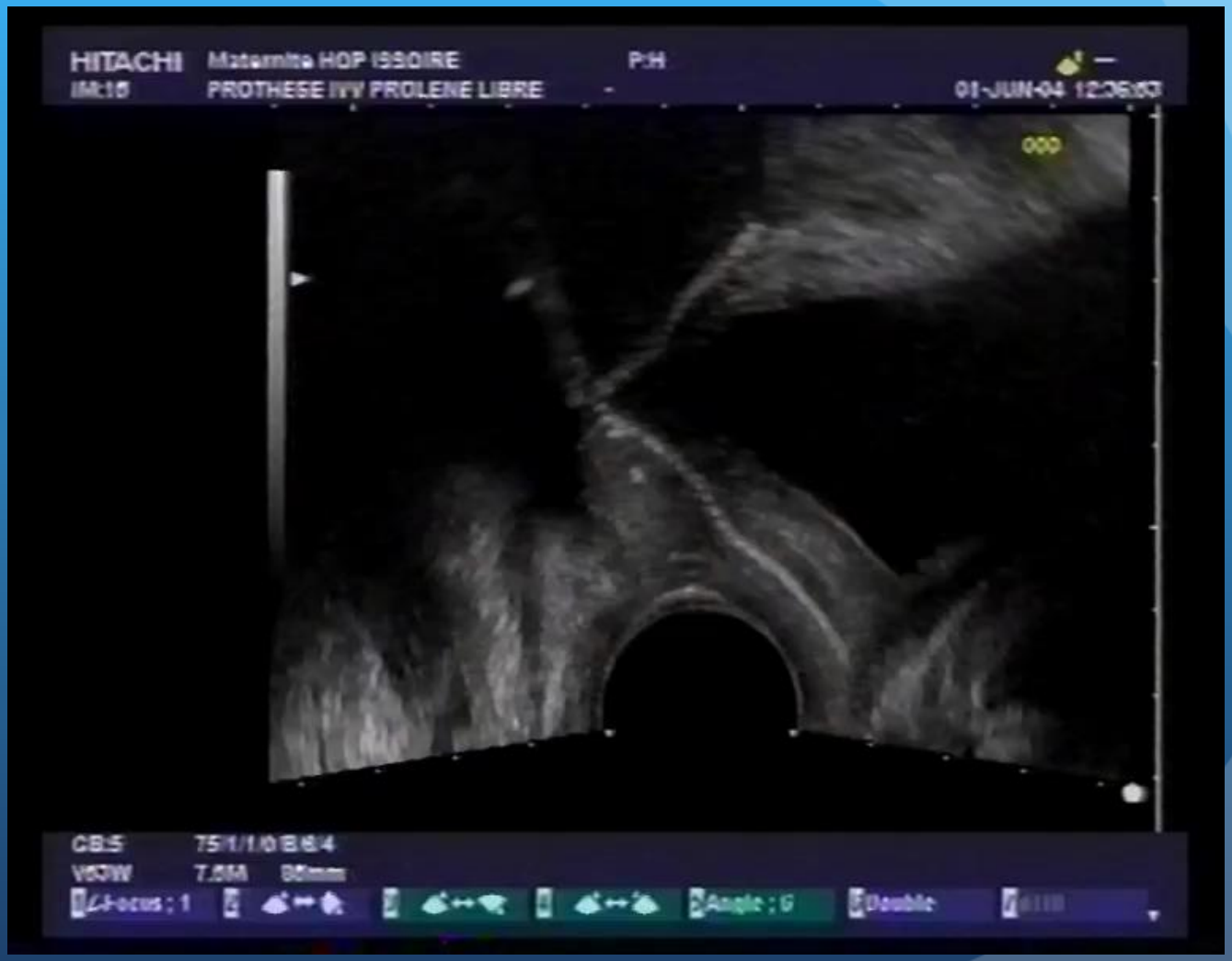

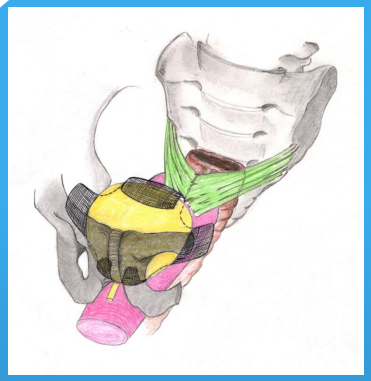

Unfixed anterior Novasilk° mesh Ultra light 22g/m2

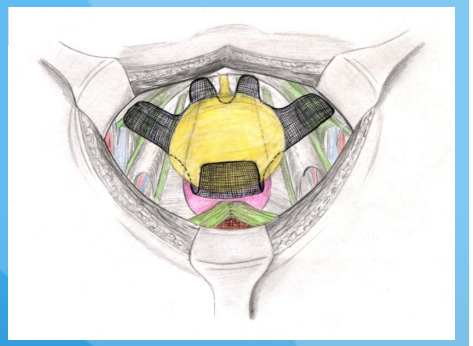

- Cohort of 90 patients operated between 1/06/2006 et 31/01/2008
- 60 patients had 6 years follow-up
- Mean follow-up: 78 months (62-88)
- Mean age : 64,5 yrs
- Concomittent surgery : vaginal hysterectomy : 52/60, prior hysterectomy :6, uterine conservation Richardson : 2
- Mac Call : 60/60, Richter 16/60

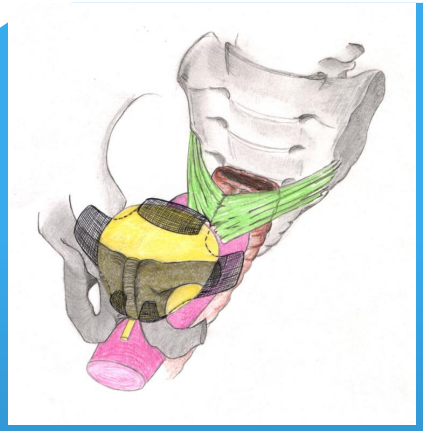

Unfixed anterior Novasilk° mesh Ultra light 22g/m2

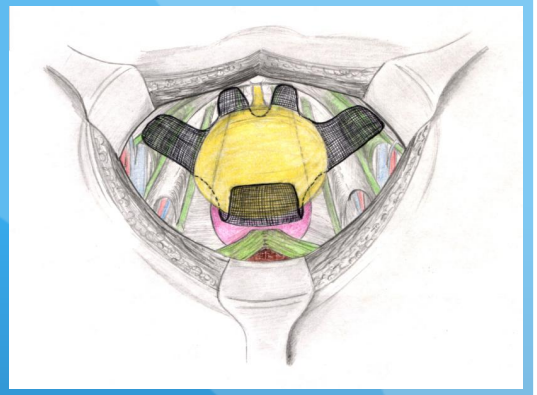

- Intra operative complications :
  - Blader or rectal injury : 0 pat
  - Blood loss : 2 pat > 500 ml
- Re-operation : 4/60 (6,7%) 2/60 (3,3%) in relation to prolapse surgery
  - 1 patient had abnormal scarring vaginal vault (Mac Call) and TVT
  - 1 patient had section of TOT for urinary retention
  - 1 patient partiel excision of mesh for vaginal mesh exposition
- Not any patient had surgery for contaction of mesh, pelvic pain or recurrent prolapse
- Vaginal mesh exposition : 1/60 : 1,7 %

Reduction of vaginal mesh exposition

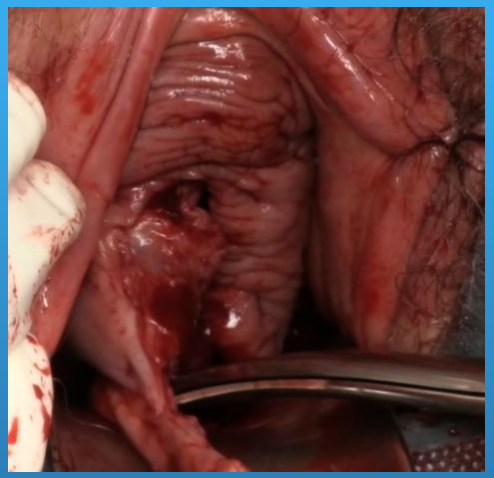

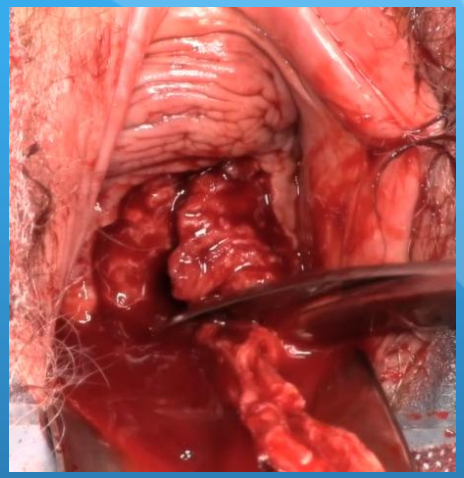

- Removing the exess mucosa sparing the well vascularized fascia

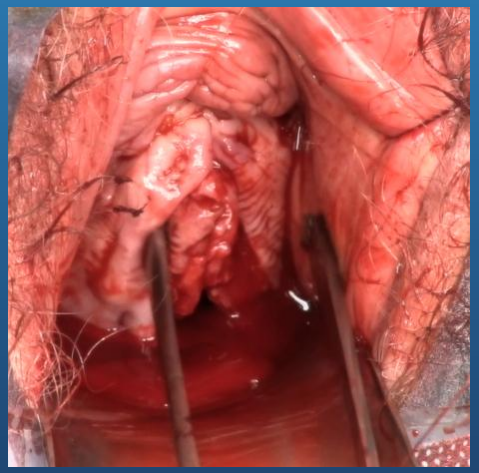

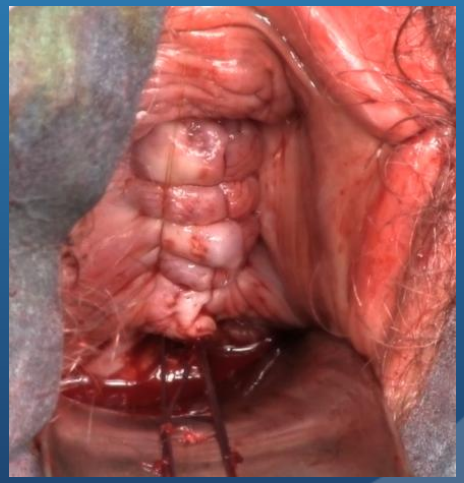

- Suturing the vagina with a double layer of fascia

Unfixed anterior Novasilk° mesh Anatomic results

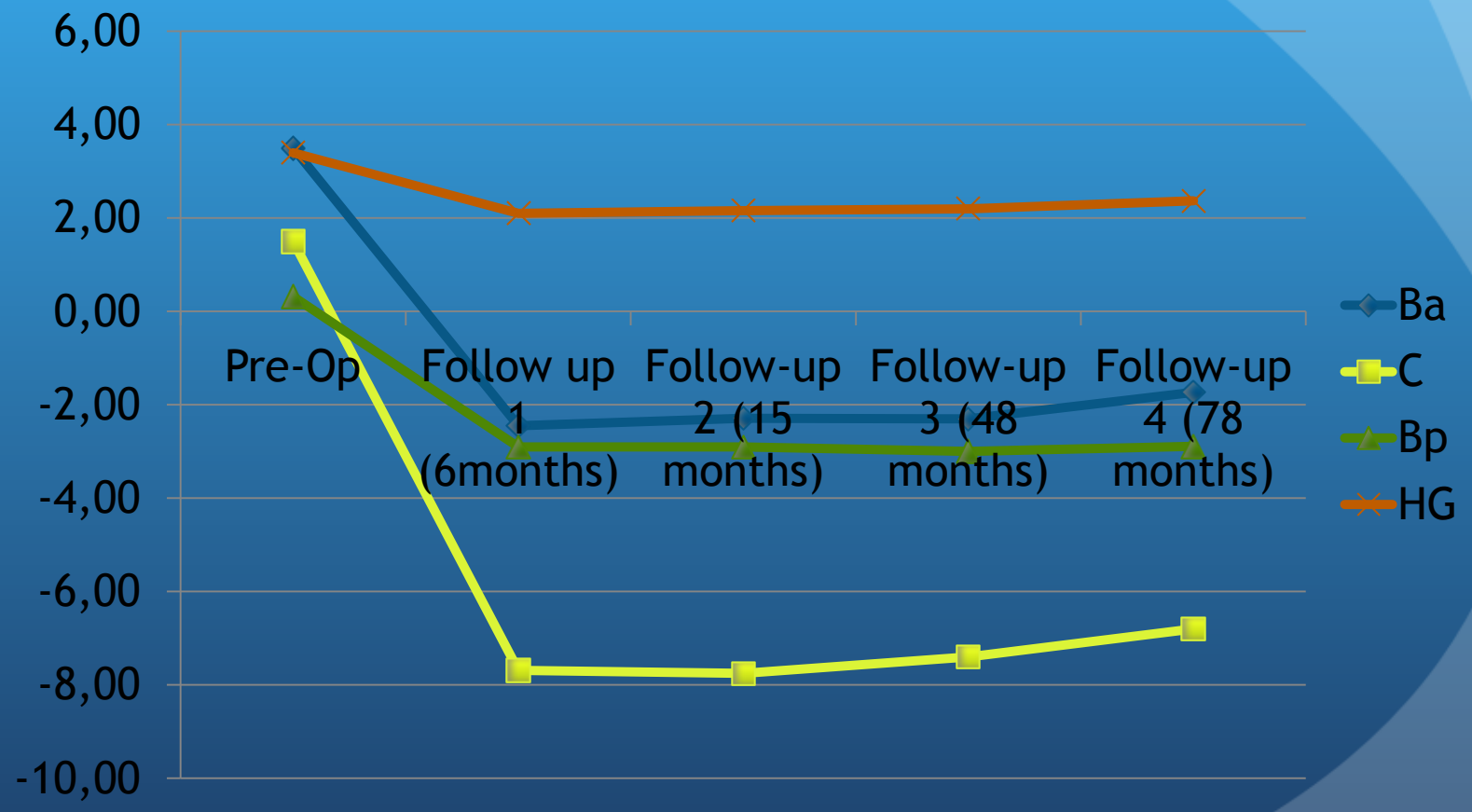

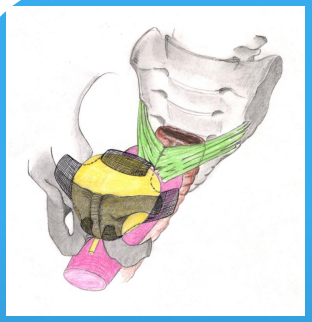

Unfixed anterior Novasilk° mesh

Anatomic results : Point Ba

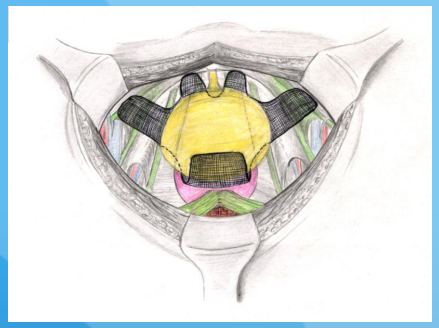

- Of 60 patients
  - Points Ba -1 : 7
  - Point Ba -0,5 : 2
  - Point Ba 0 : 8
- 17/60 (28 % stage 2 ICS) failure, or 72% good results
- Or 8/60 : 13% failures if failure is considered beyond the hymen
- Satisfaction of patients
  - **Very satisfied or satisfied : 55/60 (91,7%)**
  - Indifferent : 3/60
  - Unsatisfied : 2/60
- **Advise to best friend**
  - **Yes : 55/60 (91,7%)**
  - No : 3/60
  - No answer : 2

Conclusion

- Unfixed mesh may be a solution to contraction of mesh
  - And all its negative clinical impact of pelvic pain and dyspareunia
- Weakness of this technique
  - Does not correct para-vaginal defect
  - Anatomical results not very satisfactory
- Evolution of the technique towards temporary fixations

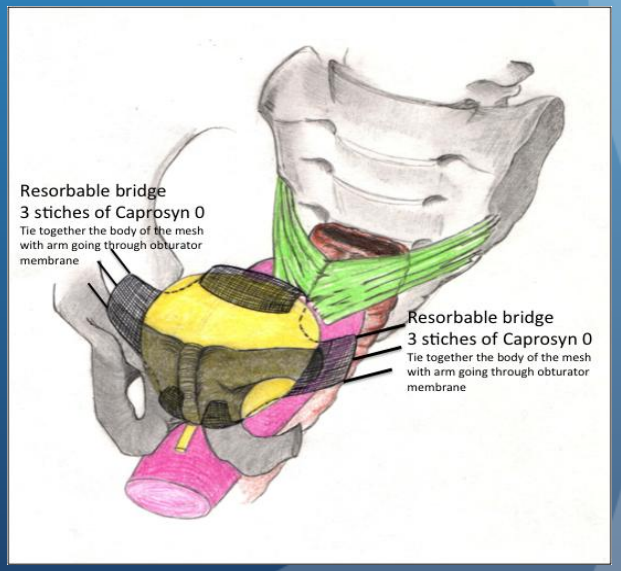

Thank you for your attention