Surgical Anatomy, basic knowledge for future activities

Stergios K. Doumouchtsis MSc, MPH, PhD, MRCOG

Consultant Subspecialist Urogynaecologist

Epsom & St Helier University Hospitals NHS Trust

Visiting Professor

University of Athens

Anatomy of the Pelvis

- Concepts
- Hypotheses
- Theories
- Cross sectional anatomy
  - Cadavers
  - Imaging
- 3D / 4D Rendering
- Biomechanics studies and models

Integral Theory

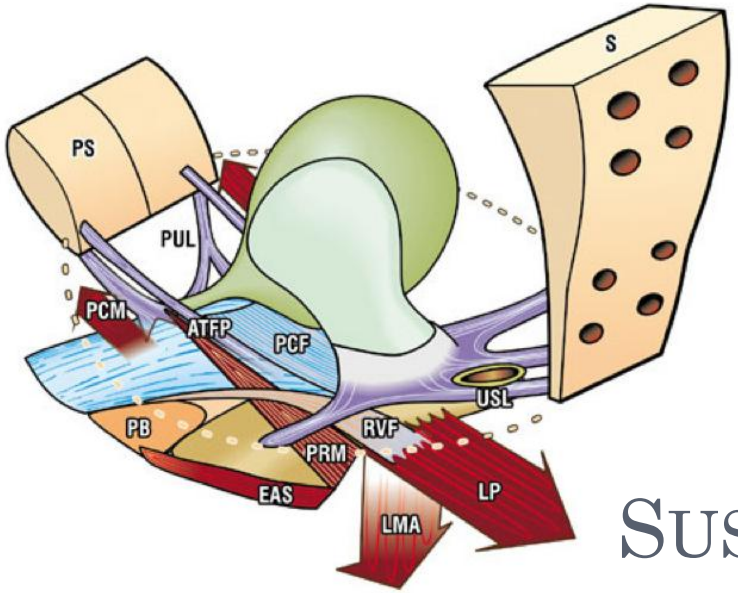

Suspension Bridge Analogy

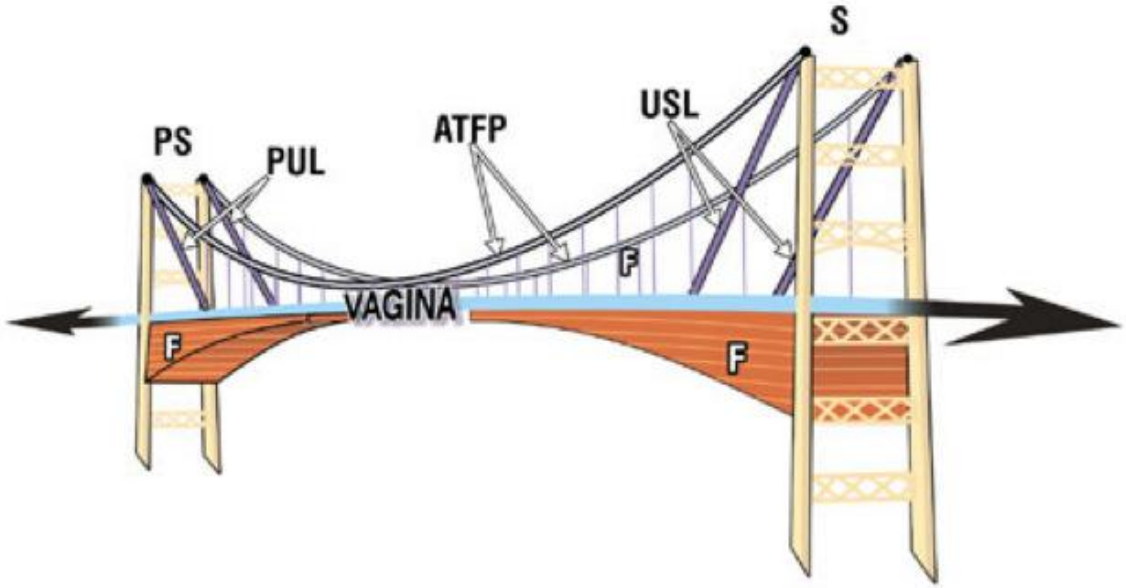

Boat in dock analogy (P. Norton)

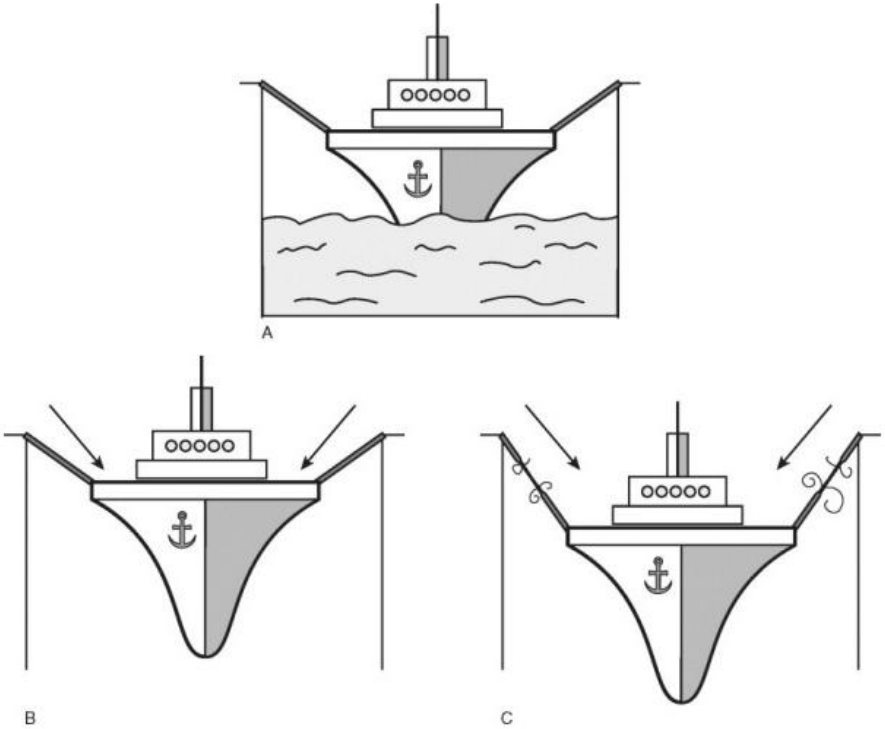

Figure 27-3 In this representation of the pelvic floor support mechanism, water represents the pelvic floor musculature, the guy ropes are the ligaments, and the ship is the pelvic organs **(A)**. If the pelvic muscles are weakened, undue force is applied to the ligaments **(B)**, which weaken and may be damaged **(C)**.

- Boat- pelvic organs
- Water- levator muscles
- Moorings- ligaments
- Problem:
  - Water
  - Moorings

Raz: Female Urology, 3rd ed Suanders, 2008

The Pelvic Trampoline

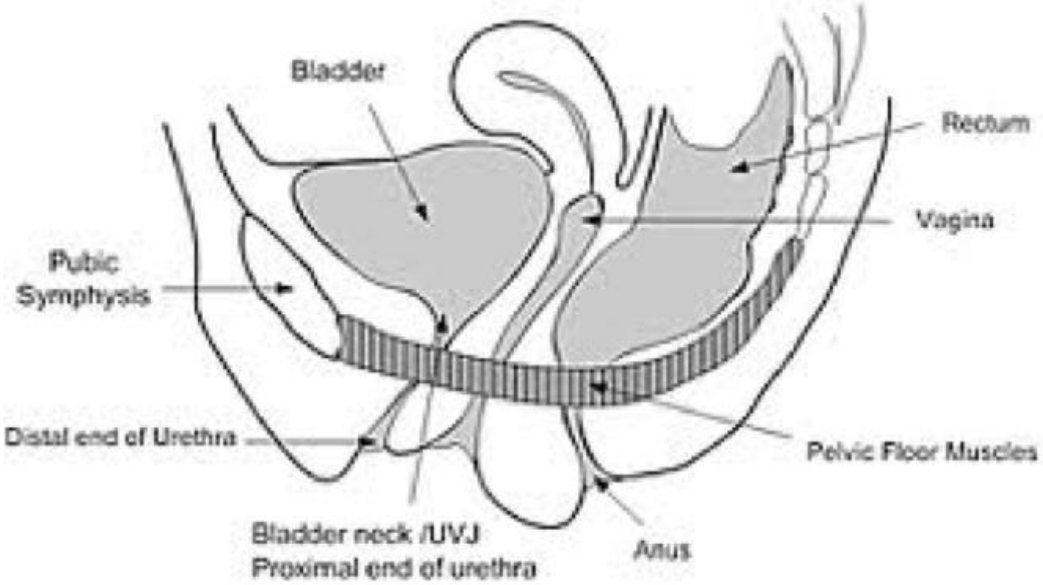

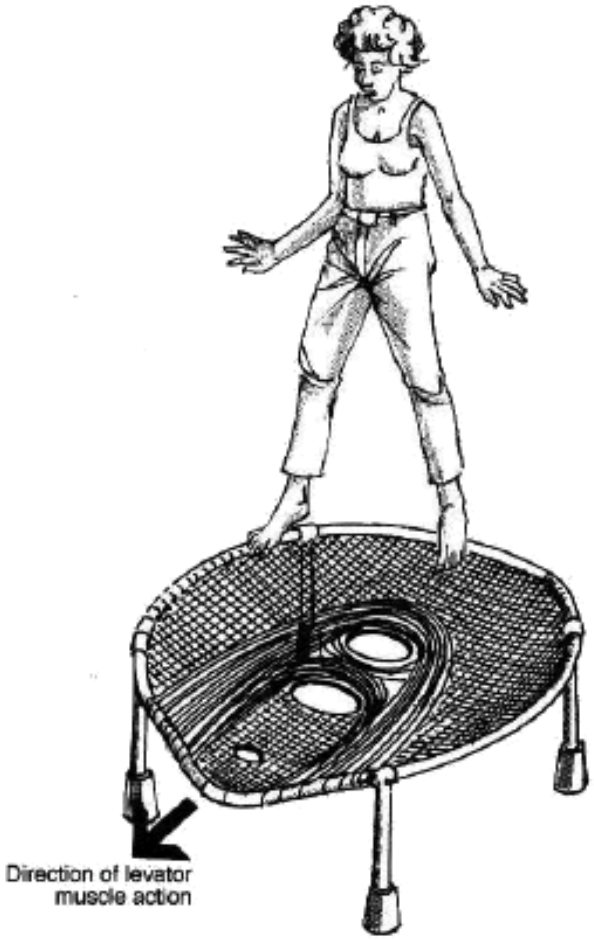

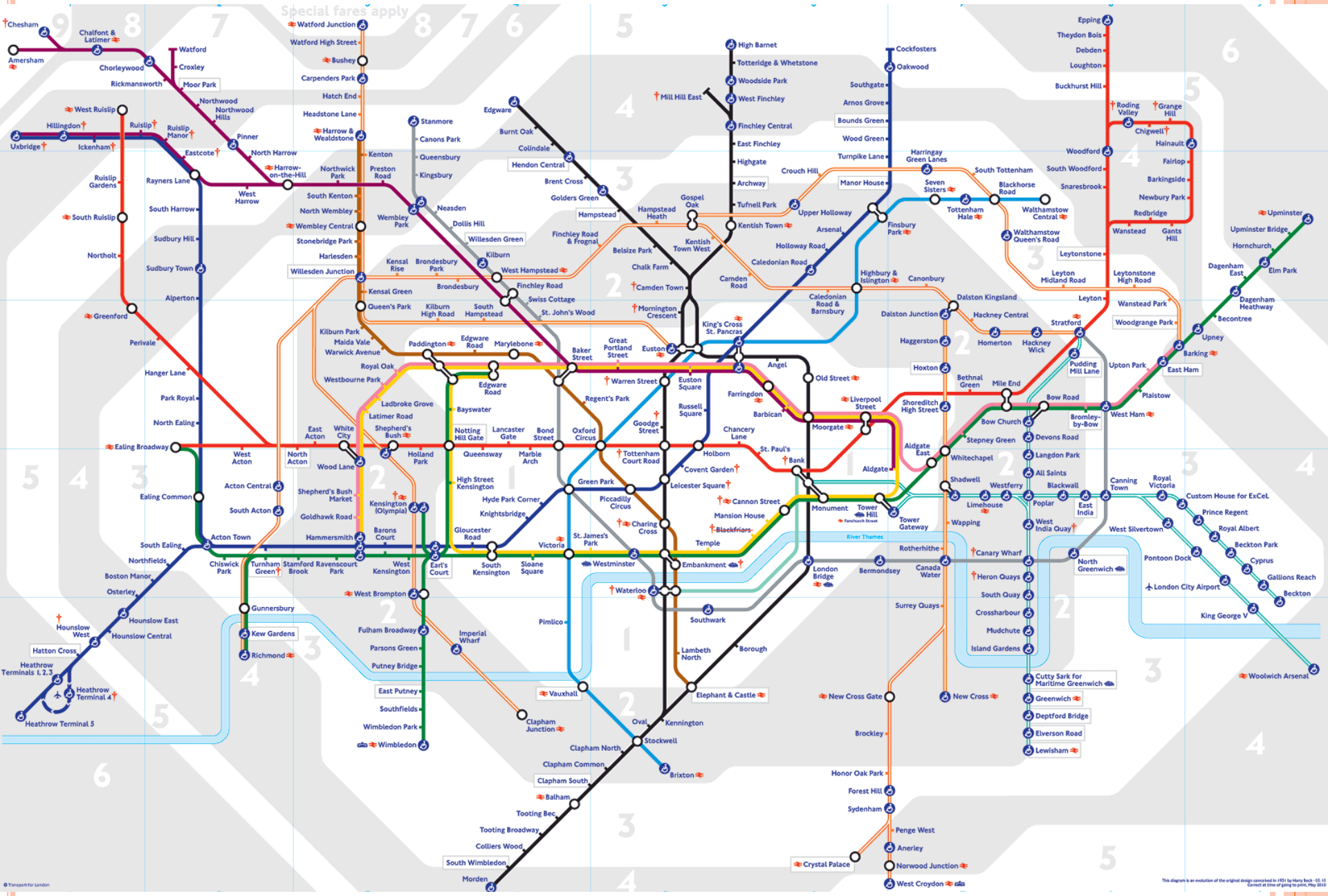
Special fares apply
Chesham
Amersham
Chalfont & Latimer
Chorleywood
Rickmansworth
Watford
Croxley
Moor Park
Northwood
Northwood Hills
Pinner
North Harrow
Harrow-on-the-Hill
West Ruislip
Hillingdon
Uxbridge
Ickenham
Ruislip
Ruislip Manor
Eastcote
Ruislip Gardens
Rayners Lane
West Harrow
South Harrow
South Ruislip
Sudbury Hill
Northolt
Sudbury Town
Alperton
Greenford
Perivale
Hanger Lane
Park Royal
North Ealing
Ealing Broadway
West Acton
North Acton
Ealing Common
Acton Central
South Acton
Acton Town
South Ealing
Northfields
Boston Manor
Osterley
Hounslow East
Hounslow West
Hounslow Central
Hatton Cross
Heathrow Terminals 1, 2, 3
Heathrow Terminal 4
Heathrow Terminal 5
Watford Junction
Watford High Street
Bushey
Carpenders Park
Hatch End
Headstone Lane
Harrow & Wealdstone
Kenton
Preston Road
Northwick Park
South Kenton
North Wembley
Wembley Central
Stonebridge Park
Harlesden
Willesden Junction
Kensal Green
Queen's Park
Kilburn High Road
South Hampstead
Kilburn Park
Maida Vale
Warwick Avenue
Royal Oak
Westbourne Park
Paddington
Edgware Road
Marylebone
Ladbroke Grove
Latimer Road
Shepherd's Bush
East Acton
White City
Wood Lane
Holland Park
Notting Hill Gate
Queensway
Lancaster Gate
Marble Arch
Bond Street
Oxford Circus
Baker Street
Great Portland Street
Euston
Euston Square
Warren Street
Regent's Park
Goodge Street
Tottenham Court Road
Holborn
Covent Garden
Leicester Square
Charing Cross
Embankment
Temple
Mansion House
Cannon Street
Blackfriars
Monument
Tower Hill
Fenchurch Street
Tower Gateway
Aldgate
Aldgate East
Liverpool Street
Moorgate
Barbican
Farringdon
Angel
Old Street
Bank
St. Paul's
Chancery Lane
Russell Square
Kensington (Olympia)
Barons Court
Hammersmith
Goldhawk Road
Shepherd's Bush Market
Bayswater
High Street Kensington
Hyde Park Corner
Knightsbridge
Gloucester Road
Green Park
Piccadilly Circus
Victoria
St. James's Park
Westminster
Waterloo
Southwark
Lambeth North
Elephant & Castle
Borough
Pimlico
Vauxhall
Oval
Kennington
Stockwell
Brixton
Clapham Junction
Clapham North
Clapham Common
Clapham South
Balham
Tooting Bec
Tooting Broadway
Colliers Wood
South Wimbledon
Morden
Chiswick Park
Turnham Green
Stamford Brook
Ravenscourt Park
West Kensington
Earl's Court
South Kensington
Sloane Square
West Brompton
Fulham Broadway
Parsons Green
Putney Bridge
East Putney
Southfields
Wimbledon Park
Wimbledon
Gunnersbury
Kew Gardens
Richmond
Imperial Wharf
Stanmore
Canons Park
Queensbury
Kingsbury
Edgware
Burnt Oak
Colindale
Hendon Central
Brent Cross
Golders Green
Hampstead
Hampstead Heath
Finchley Road & Frognal
Wembley Park
Neasden
Dollis Hill
Willesden Green
Kilburn
West Hampstead
Finchley Road
Swiss Cottage
St. John's Wood
Kensal Rise
Brondesbury Park
Brondesbury
Belsize Park
Chalk Farm
Camden Town
Mornington Crescent
Kentish Town West
Gospel Oak
Kentish Town
Tufnell Park
Archway
Highgate
East Finchley
Finchley Central
West Finchley
Woodside Park
Totteridge & Whetstone
High Barnet
Mill Hill East
Camden Road
Caledonian Road
Holloway Road
Arsenal
Upper Holloway
Crouch Hill
Harringay Green Lanes
Manor House
Turnpike Lane
Wood Green
Bounds Green
Arnos Grove
Southgate
Oakwood
Cockfosters
Seven Sisters
Tottenham Hale
South Tottenham
Blackhorse Road
Walthamstow Central
Walthamstow Queen's Road
Finsbury Park
Highbury & Islington
Canonbury
Caledonian Road & Barnsbury
Dalston Kingsland
Dalston Junction
Hackney Central
Haggerston
Homerton
Hackney Wick
Hoxton
Bethnal Green
Mile End
Shoreditch High Street
Stratford
Pudding Mill Lane
Bow Road
Bow Church
Bromley-by-Bow
West Ham
Devons Road
Langdon Park
All Saints
Stepney Green
Whitechapel
Shadwell
Westferry
Limehouse
Poplar
Blackwall
East India
Canning Town
Royal Victoria
Wapping
West India Quay
Canary Wharf
Rotherhithe
Canada Water
Bermondsey
London Bridge
River Thames
Surrey Quays
Heron Quays
South Quay
Crossharbour
Mudchute
Island Gardens
North Greenwich
Cutty Sark for Maritime Greenwich
Greenwich
Deptford Bridge
Elverson Road
Lewisham
New Cross
New Cross Gate
Brockley
Honor Oak Park
Forest Hill
Sydenham
Penge West
Anerley
Norwood Junction
West Croydon
Crystal Palace
Epping
Theydon Bois
Debden
Loughton
Buckhurst Hill
Roding Valley
Grange Hill
Chigwell
Hainault
Woodford
South Woodford
Snaresbrook
Fairlop
Barkingside
Newbury Park
Redbridge
Wanstead
Gants Hill
Leytonstone
Leyton Midland Road
Leytonstone High Road
Leyton
Wanstead Park
Woodgrange Park
Upton Park
East Ham
Upminster
Upminster Bridge
Hornchurch
Elm Park
Dagenham East
Dagenham Heathway
Becontree
Upney
Barking
Plaistow
Custom House for ExCeL
Prince Regent
Royal Albert
West Silvertown
Beckton Park
Cyprus
Gallions Reach
Beckton
Pontoon Dock
London City Airport
King George V
Woolwich Arsenal
© Transport for London
This diagram is an evolution of the original design conceived in 1931 by Harry Beck - 05.10
Correct at time of going to print, May 2010

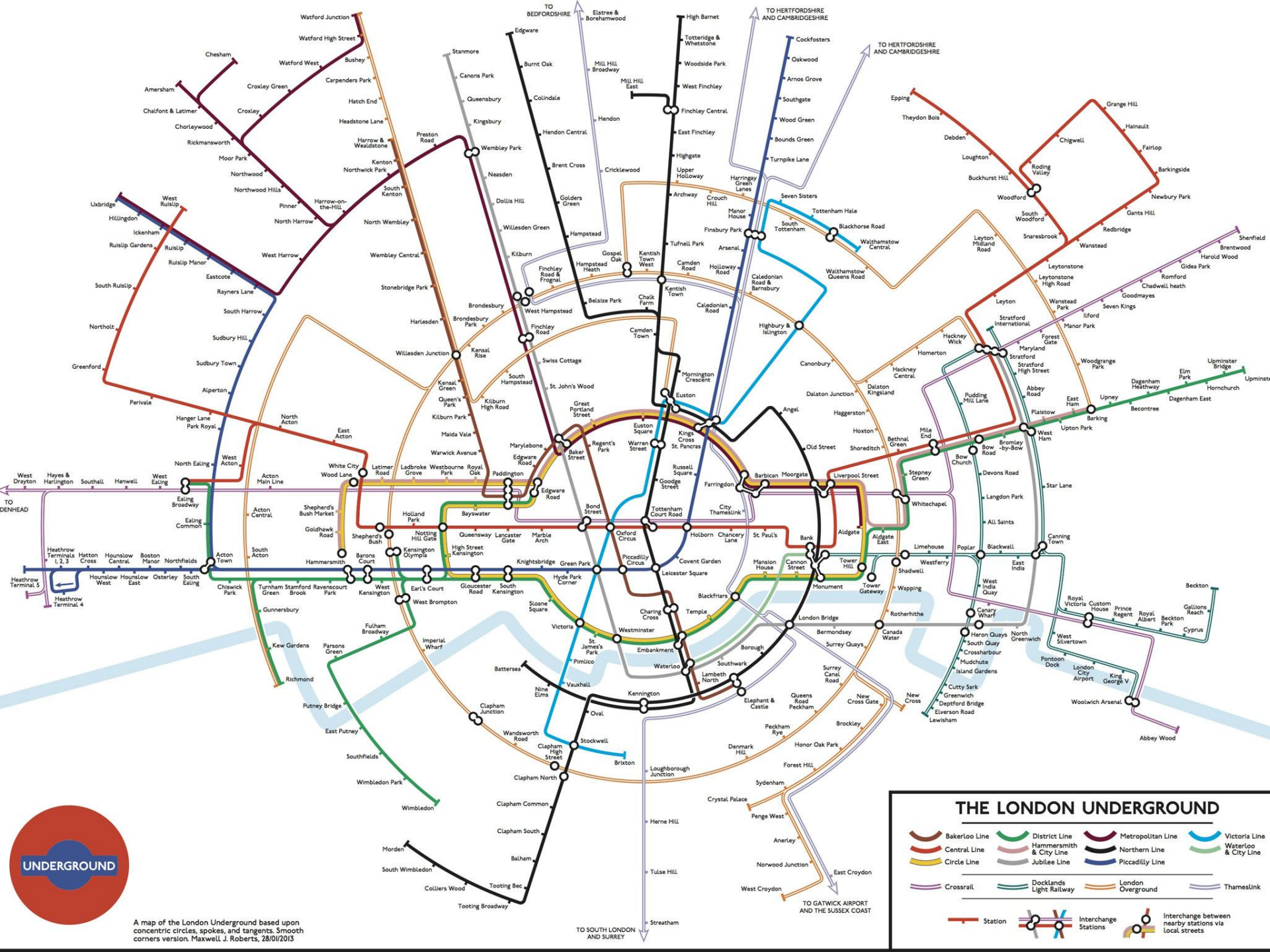

THE LONDON UNDERGROUND

A map of the London Underground based upon concentric circles, spokes, and tangents. Smooth corners version. Maxwell J. Roberts, 28/01/2013

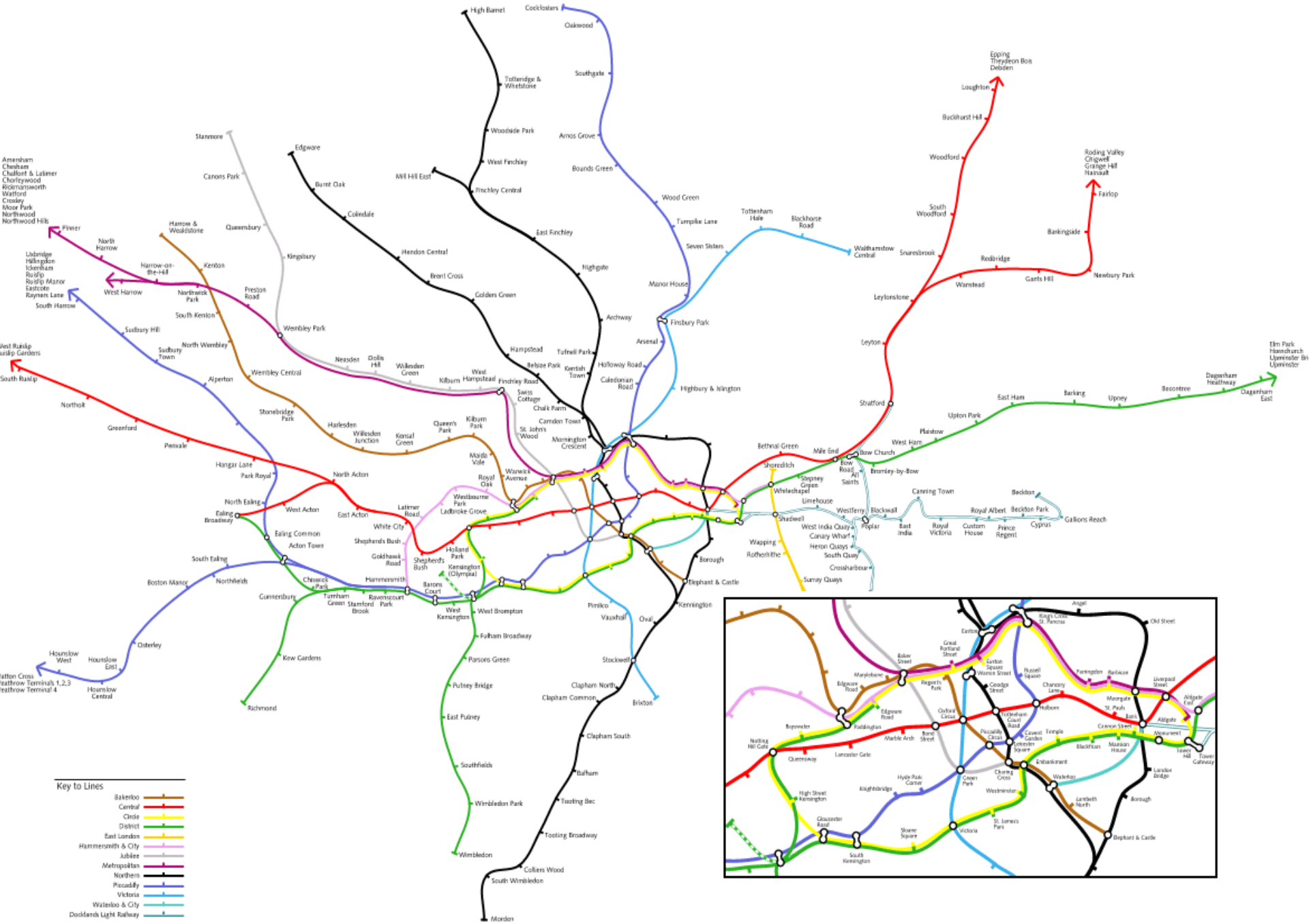
Key to Lines
Bakerloo
Central
Circle
District
East London
Hammersmith & City
Jubilee
Metropolitan
Northern
Piccadilly
Victoria
Waterloo & City
Docklands Light Railway

Anatomy of the Pelvis

- Bones
- Ligaments
- Muscles
- Fasciae
- Nerves
- Blood supply
- Organs

Three subsystems:

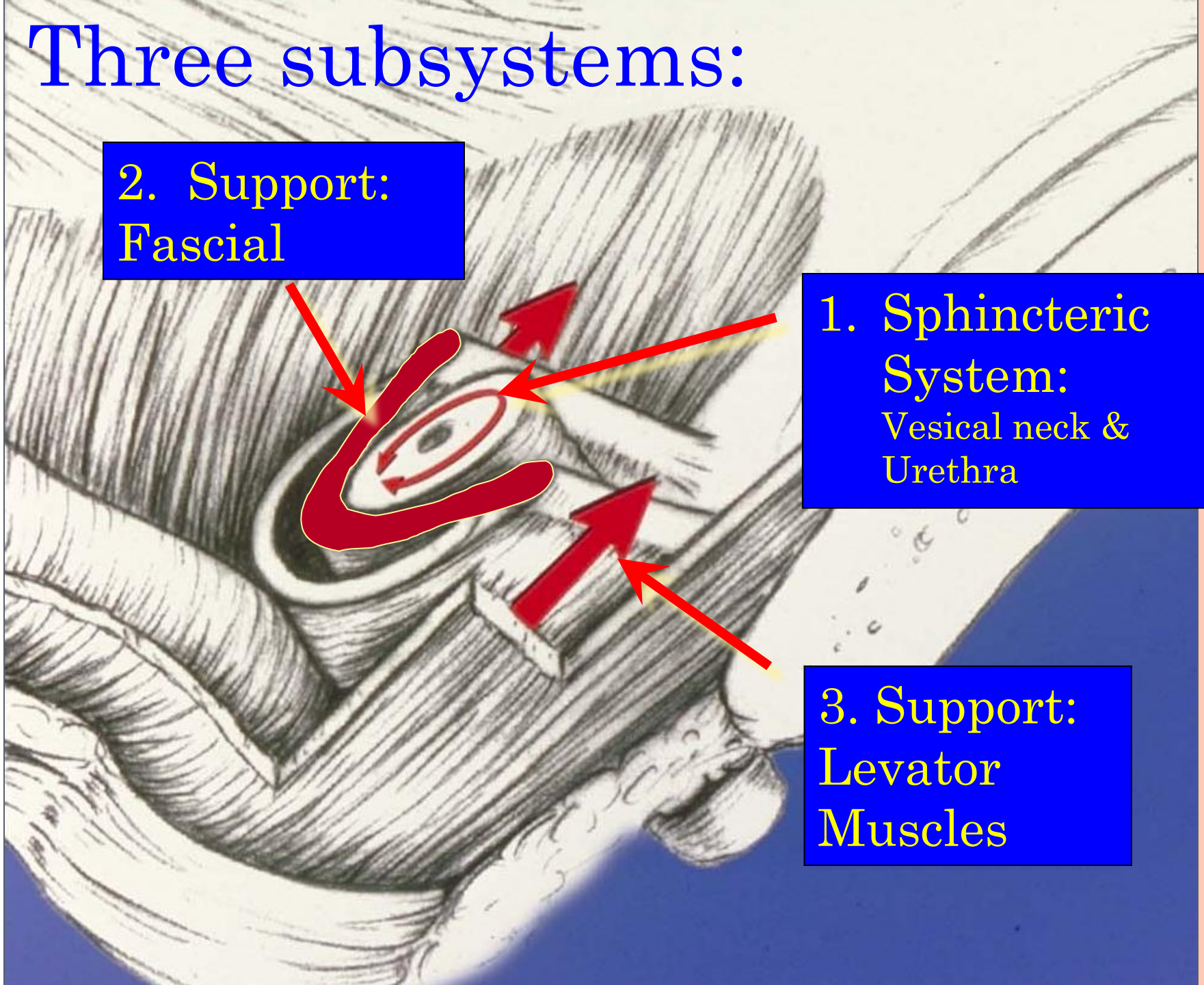

Levels of Pelvic Support

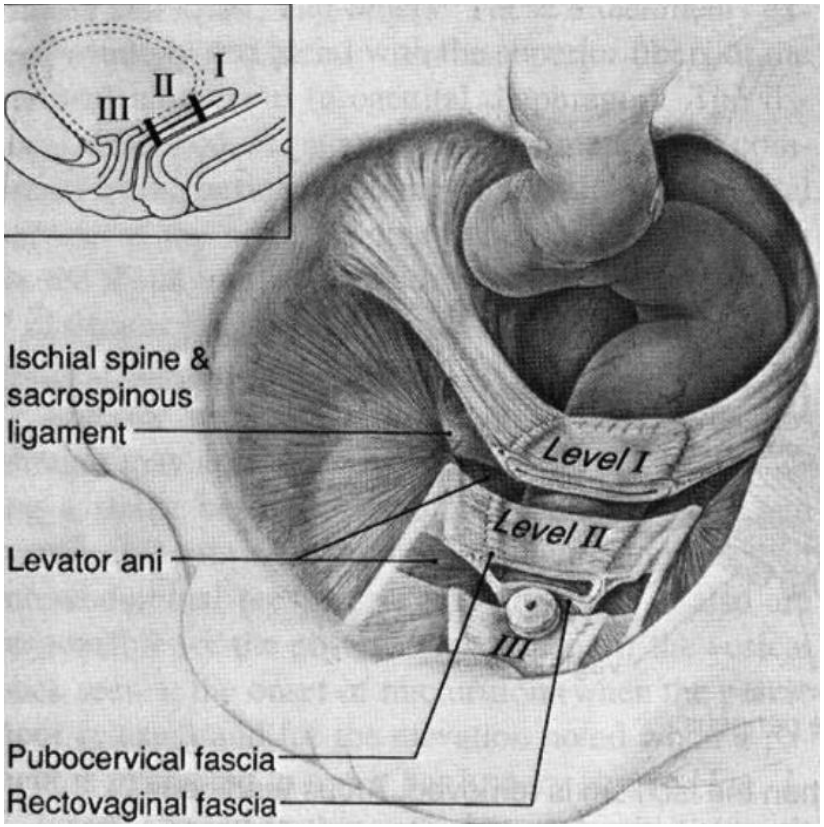

Apical **suspension**

- apex to pelvic walls and sacrum
- Damage results in prolapse of vaginal apex

Midvaginal lateral **attachment**

- Vaginal attachment to ATFP and ATLA
- Pubocervical and rectovaginal fasciae support bladder and anterior rectum
- Avulsion results in cystocele or rectocele

Distal perineal **fusion**

- Fusion of vagina to perineal membrane, body and levators
- Damage results in deficient perineal body or urethrocele

The Bones

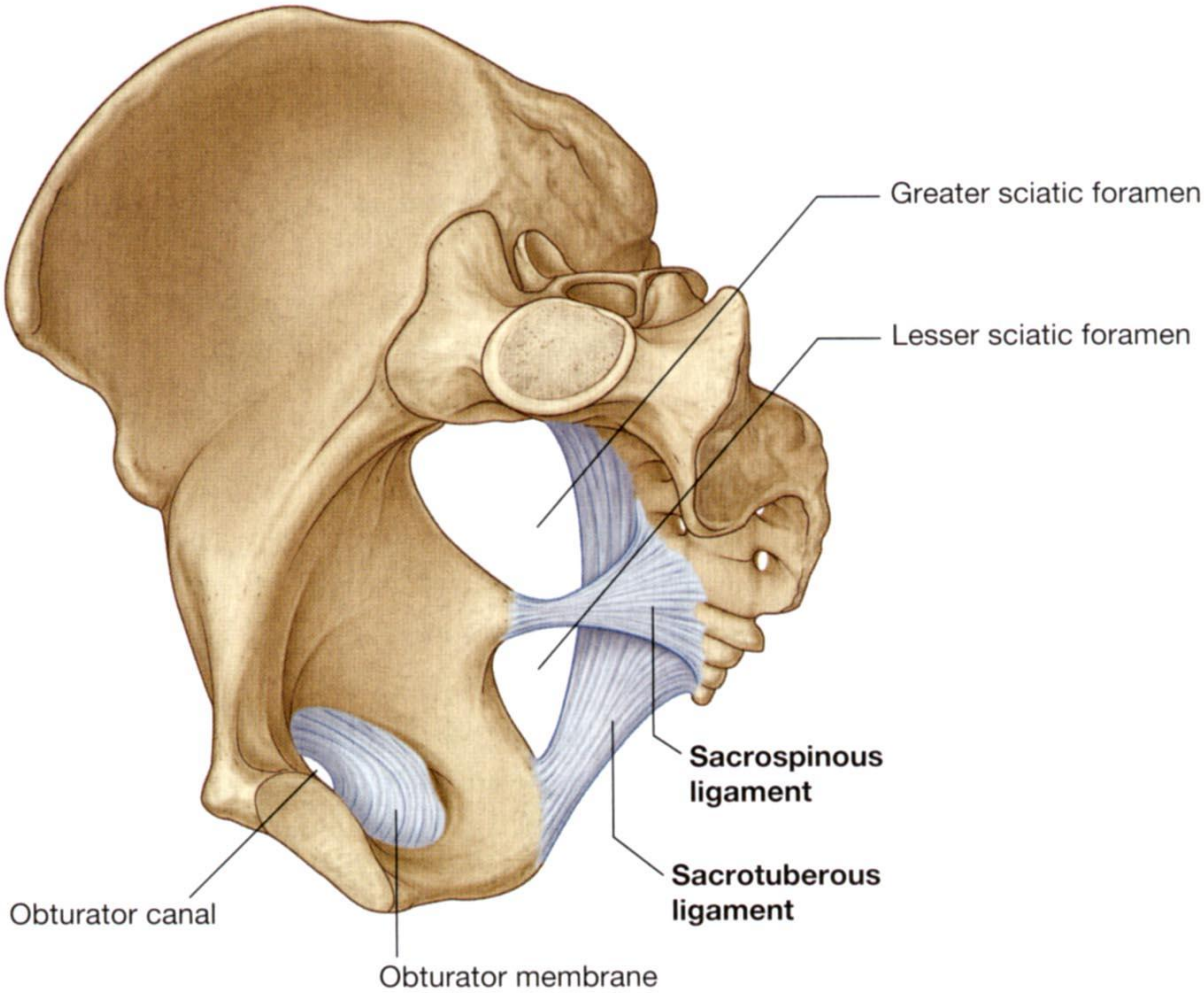
Greater sciatic foramen
Lesser sciatic foramen
Sacrospinous ligament
Sacrotuberous ligament
Obturator canal
Obturator membrane

Same Cause?

Different Cause?

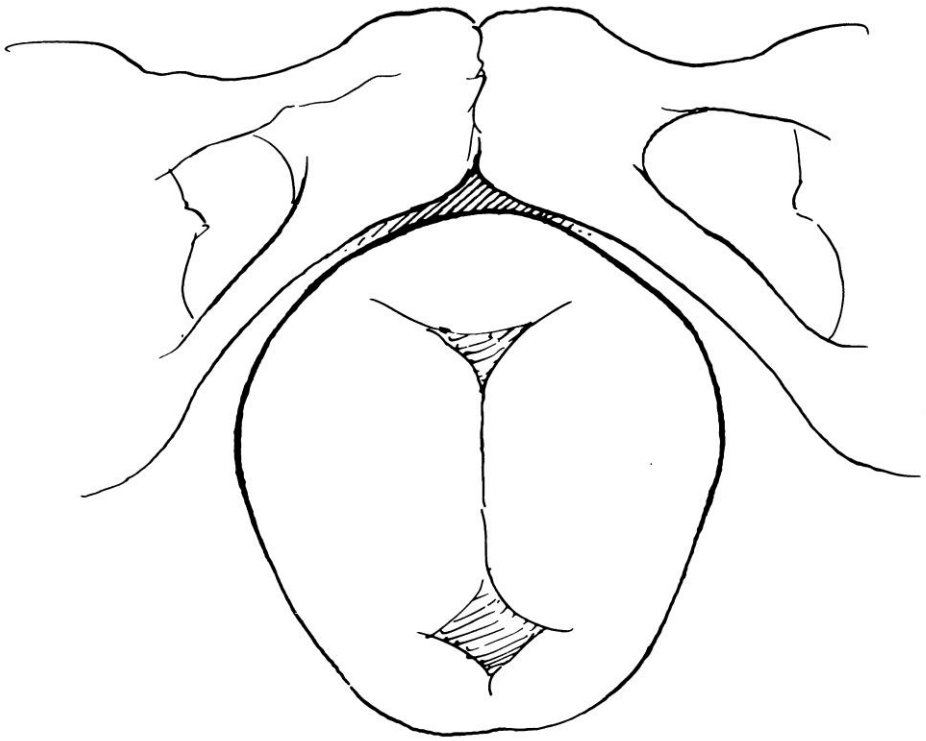

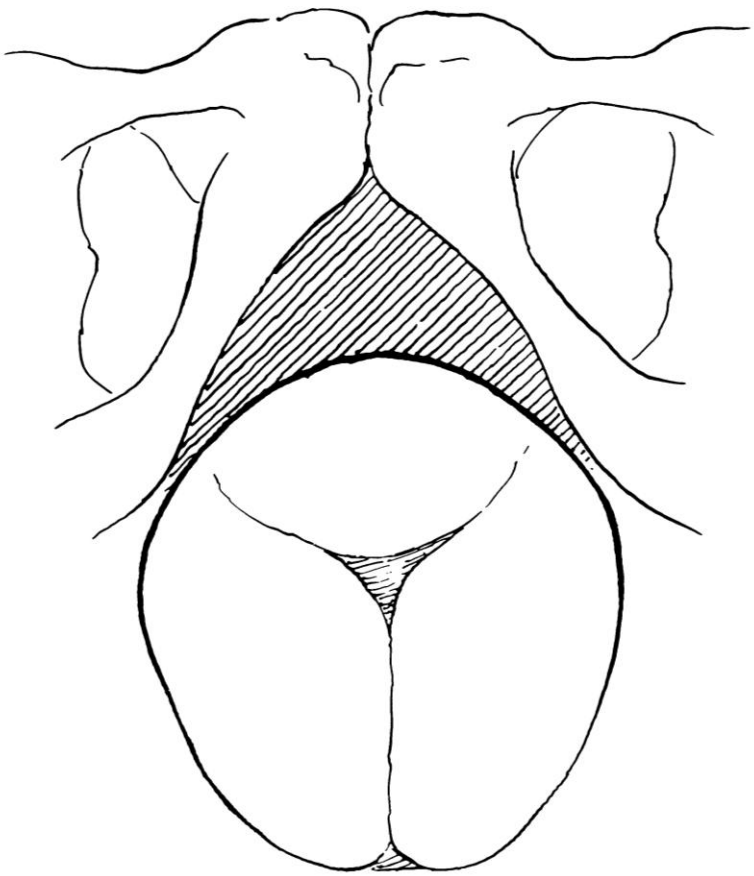

Adapted from Nichols DH, Randall CL *Vaginal Surgery Fourth Edition*.

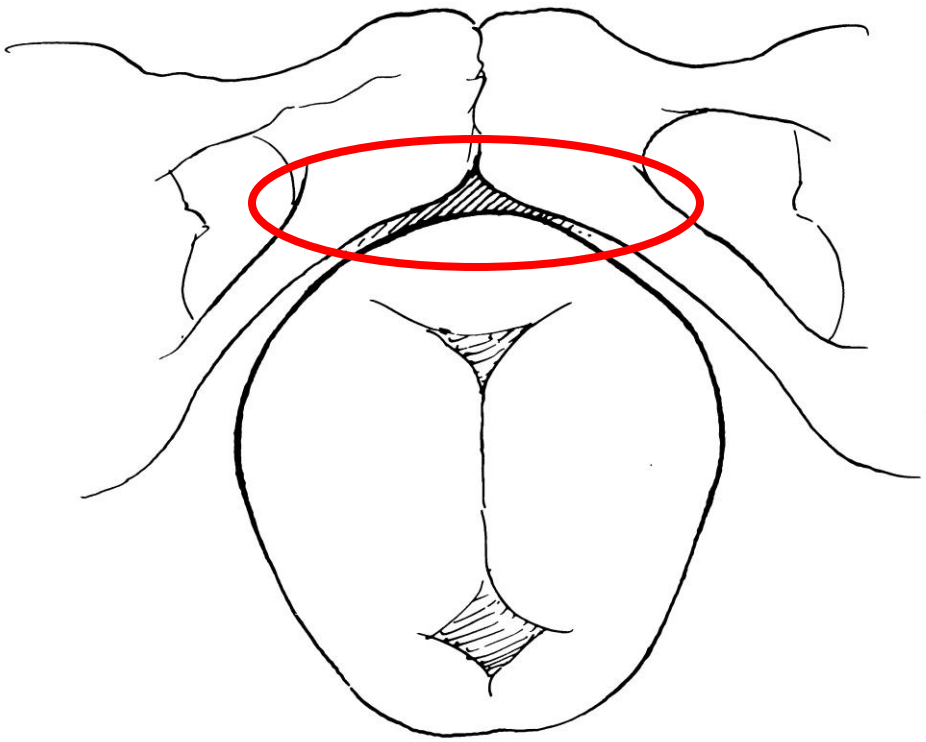

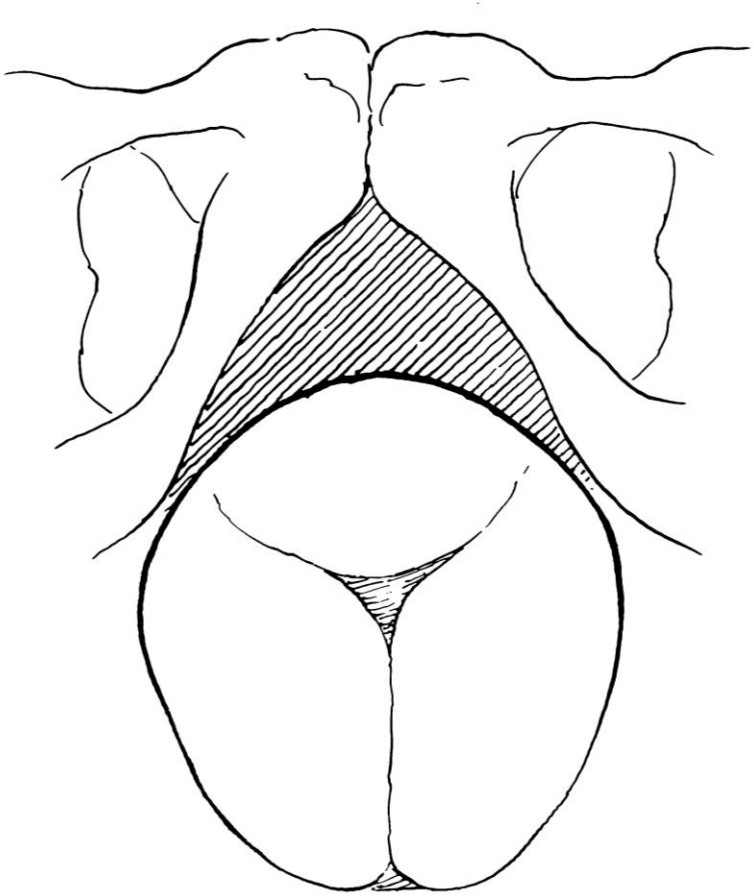

Adapted from Nichols DH, Randall CL *Vaginal Surgery Fourth Edition*.

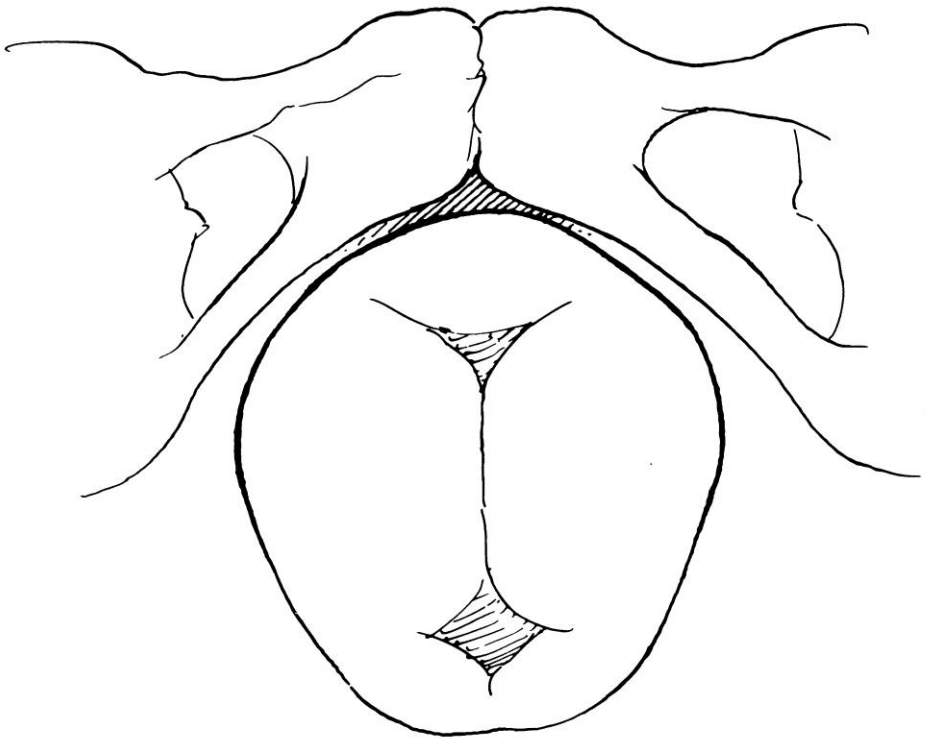

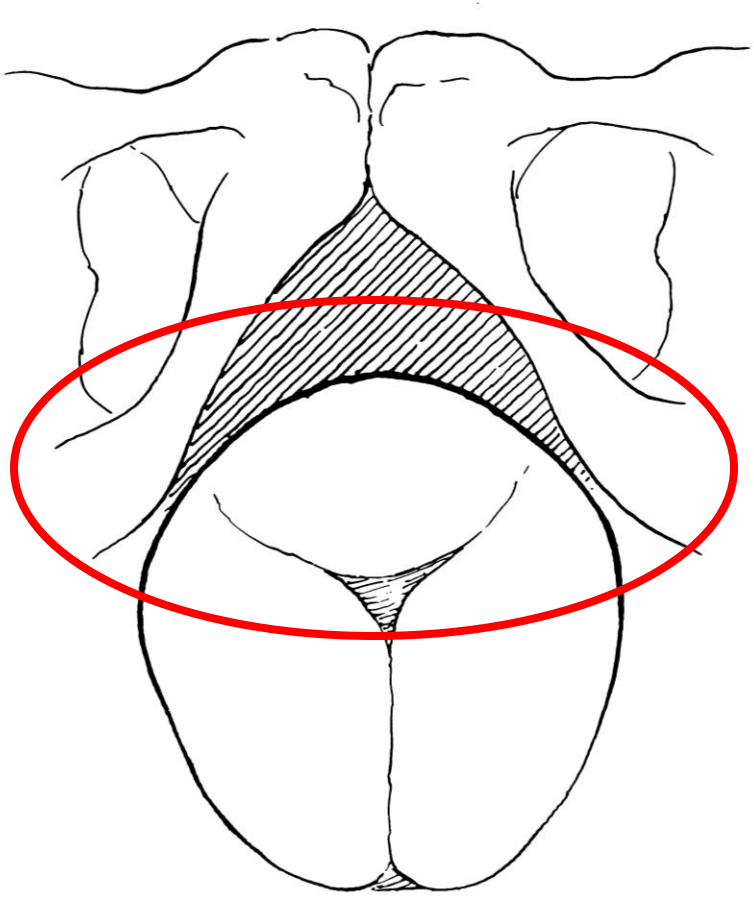

Adapted from Nichols DH, Randall CL *Vaginal Surgery Fourth Edition*.

Hypothesis:
Sphincter Compression

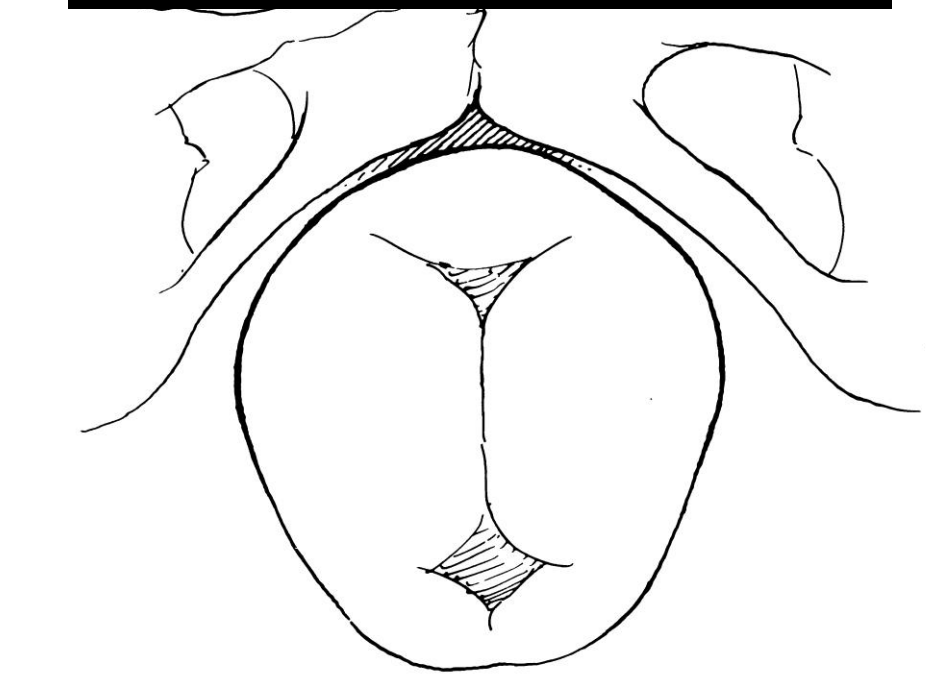

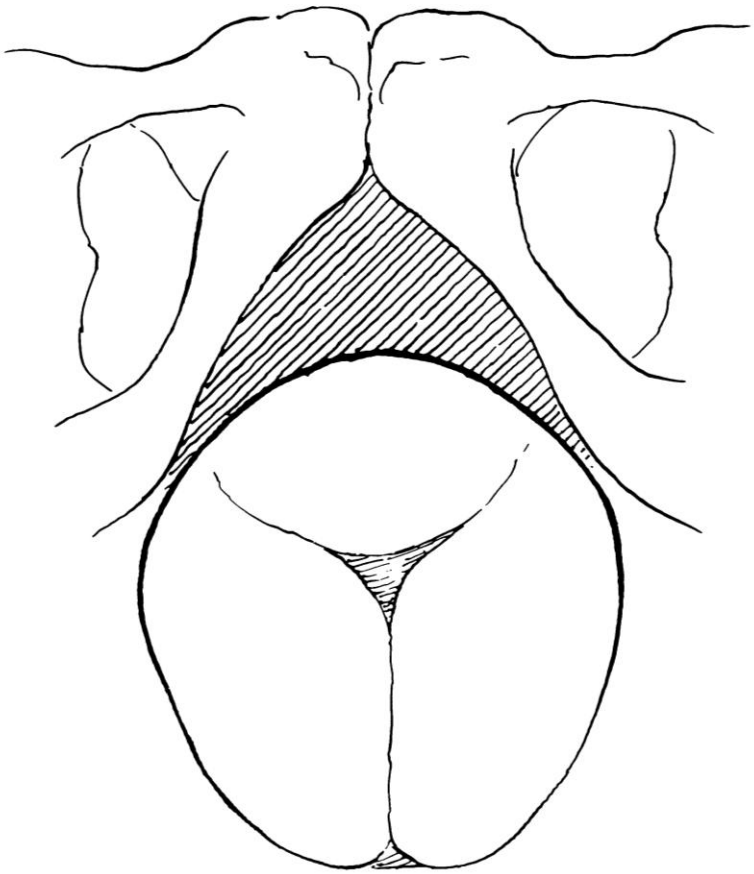

Hypothesis:
Levator Stretch

Adapted from Nichols DH, Randall CL *Vaginal Surgery Fourth Edition*.

Int Urogynecol J
DOI 10.1007/s00192-012-2028-0

ORIGINAL ARTICLE

Are bony pelvis dimensions associated with levator ani defects? A case–control study

Mitchell B. Berger · Stergios K. Doumouchtsis · John O. DeLancey

"Severe bilateral LAD are associated with shorter SCIPP length"

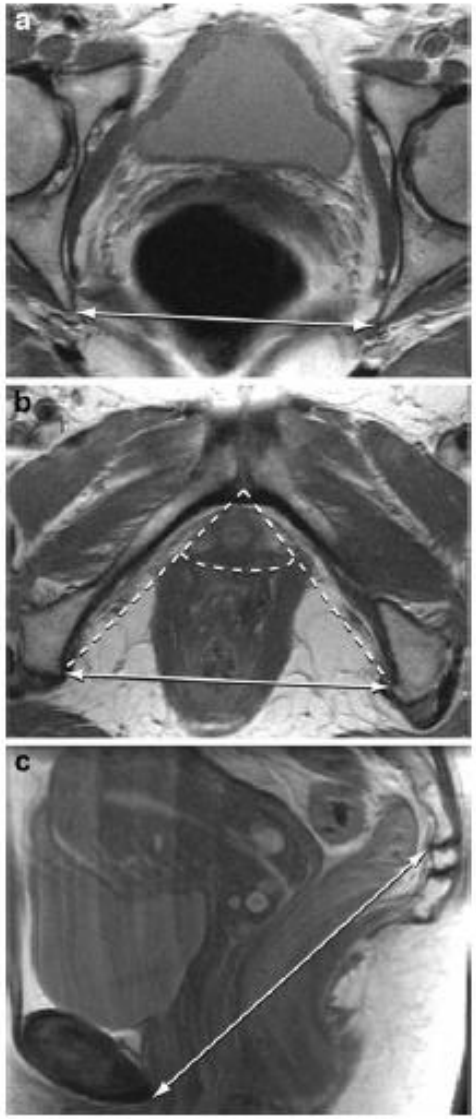

Fig. 1 **a** Axial pelvic magnetic resonance imaging (MRI) slice demonstrating the interspinous diameter (*double-headed arrow*). **b** Axial pelvic MRI slice illustrating the intertuberous diameter (*solid double-headed arrow*) and subpubic angle (*dashed lines*). **c** Sagittal pelvic MRI slice demonstrating the sacrococcygeal joint-to-infrapubic point (SCIPP) line (*double-headed arrow*)

Neurourology and Urodynamics 32:37–42 (2013)

Bony Pelvis Dimensions in Women With and Without Stress Urinary Incontinence

Mitchell B. Berger,[1*] Stergios K. Doumouchtsis,[2] and John O. DeLancey[1]
[1]*Pelvic Floor Research Group, Department of Obstetrics and Gynecology, University of Michigan, Ann Arbor, Michigan*
[2]*Department of Obstetrics and Gynecology, St. George's University of London, London, UK*

Postpartum SUI is associated with a wider subpubic angle.

By contrast, no significant differences in bony pelvis dimensions were identified when comparing **middle-aged women** with SUI and their continent controls.

Int Urogynecol J (2012) 23:1075–1080
DOI 10.1007/s00192-012-1735-x

ORIGINAL ARTICLE

Variation of distances from mid-urethra to the obturator foramen: an MRI study

Petr Hubka • Stergios K. Doumouchtsis •
Mitchell B. Berger • John O. DeLancey

"There is high variability in the distance from mid-urethra to the obturator foramina.
Height should not be used as a predictor of dimensions in the lesser pelvis".

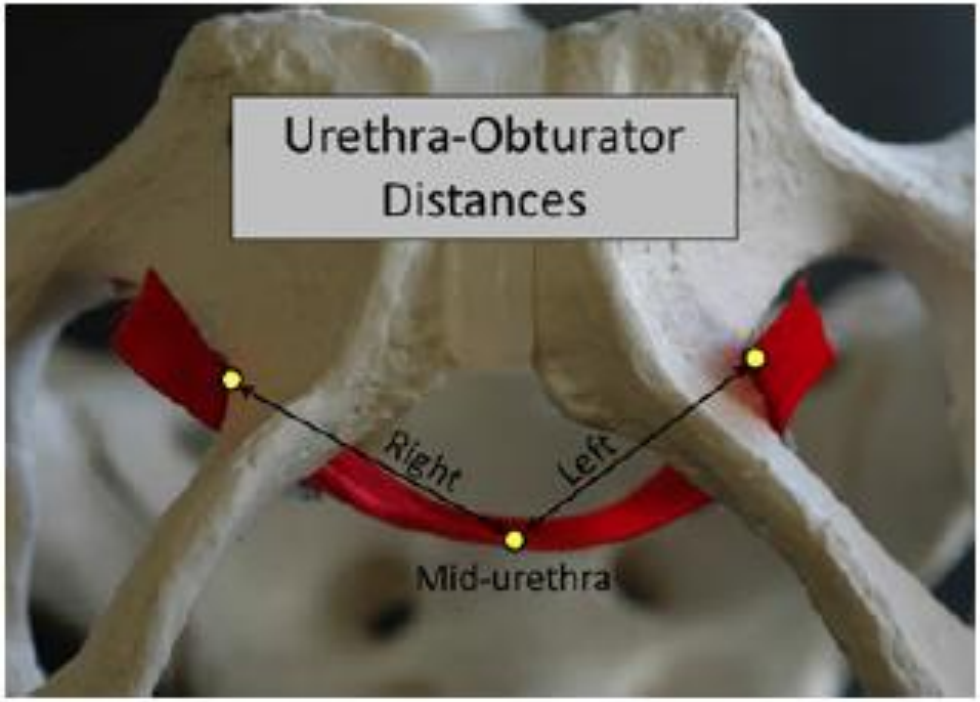

Fig. 1 Conceptual diagram showing our measurements. The red ribbon shows the expected path of the transobturator tape from the medial aspect of the obturator foramen on each side to its location at the mid-urethra in the midline. Measurements were taken from a point under the mid-urethra

The Muscles - Levator Ani

Levator ani	Origin	Insertion	Function
Pubococcygeus			
• **Puboperinealis**	Pubic bone	Perineal body	Constant tone **pulls perineal body** ventrally toward pubis
• **Pubovaginalis**	Pubic bone	Lateral vaginal wall (mid-urethral level)	**Elevates vagina** in region of mid-urethra
• **Puboanalis**	Pubic bone	Intersphincteric groove between internal and external anal sphincter; ends in the anal skin	**Elevates the anus** and the anal skin
Puborectalis	Pubic bone	Joins contralateral fibers and forms a sling behind the rectum	**Closes pelvic floor** and forms **anorectal angle**
Iliococcygeus	Tendinous arch of the levator ani	The 2 sides fuse in the iliococcygeal raphe	**Supportive diaphragm** that spans the pelvic canal

Levator ani - components

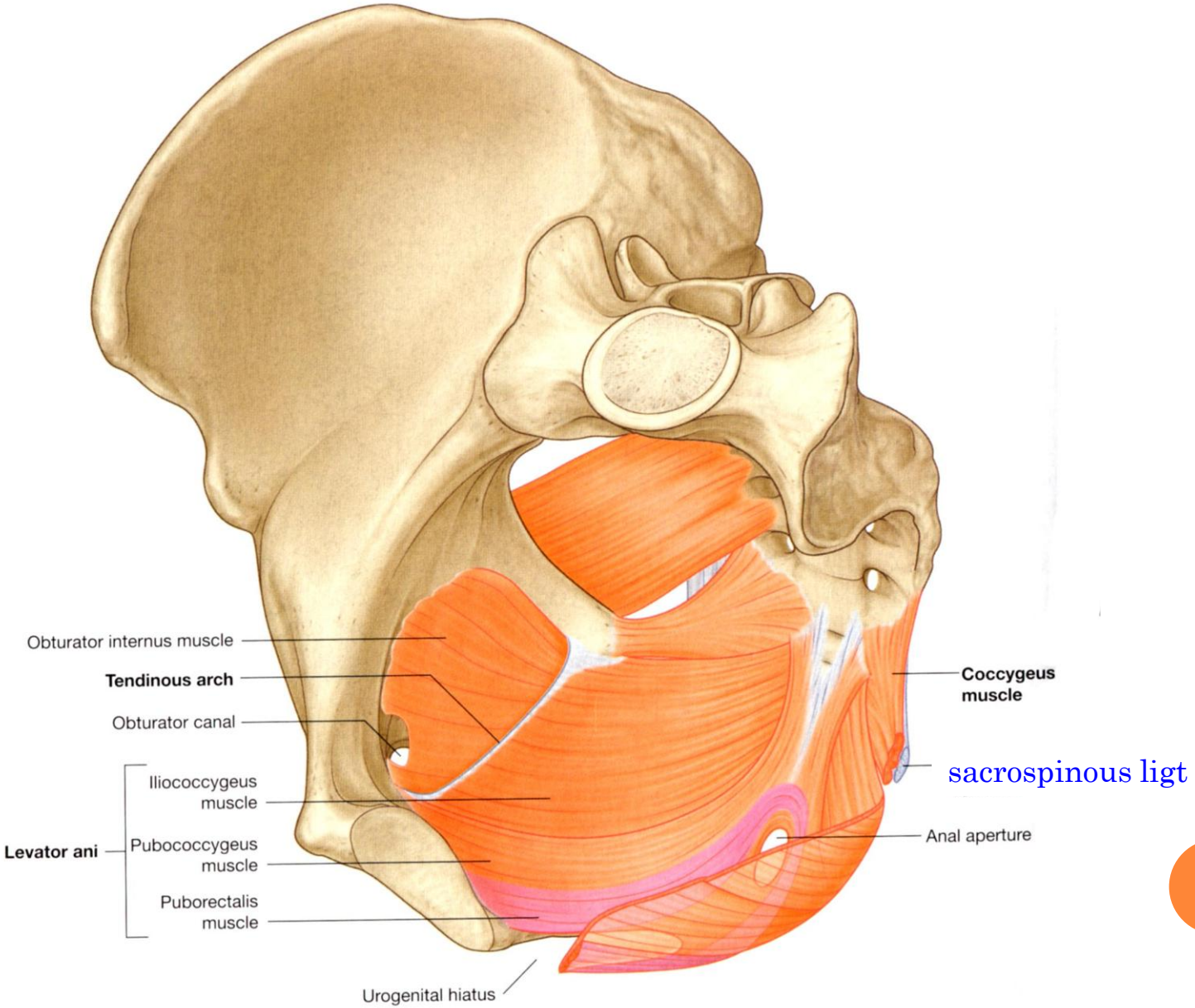

Lateral view of urethral and pelvic floor muscular anatomy

- BC bulbocavernosus
- CU compressor urethrae
- D detrusor
- LA levator ani
- US urethral sphincter
- UVS urethrovaginal sphincter

Puborectalis muscle is removed for clarity

Ashton Miller & Delancey 2007

The Fasciae

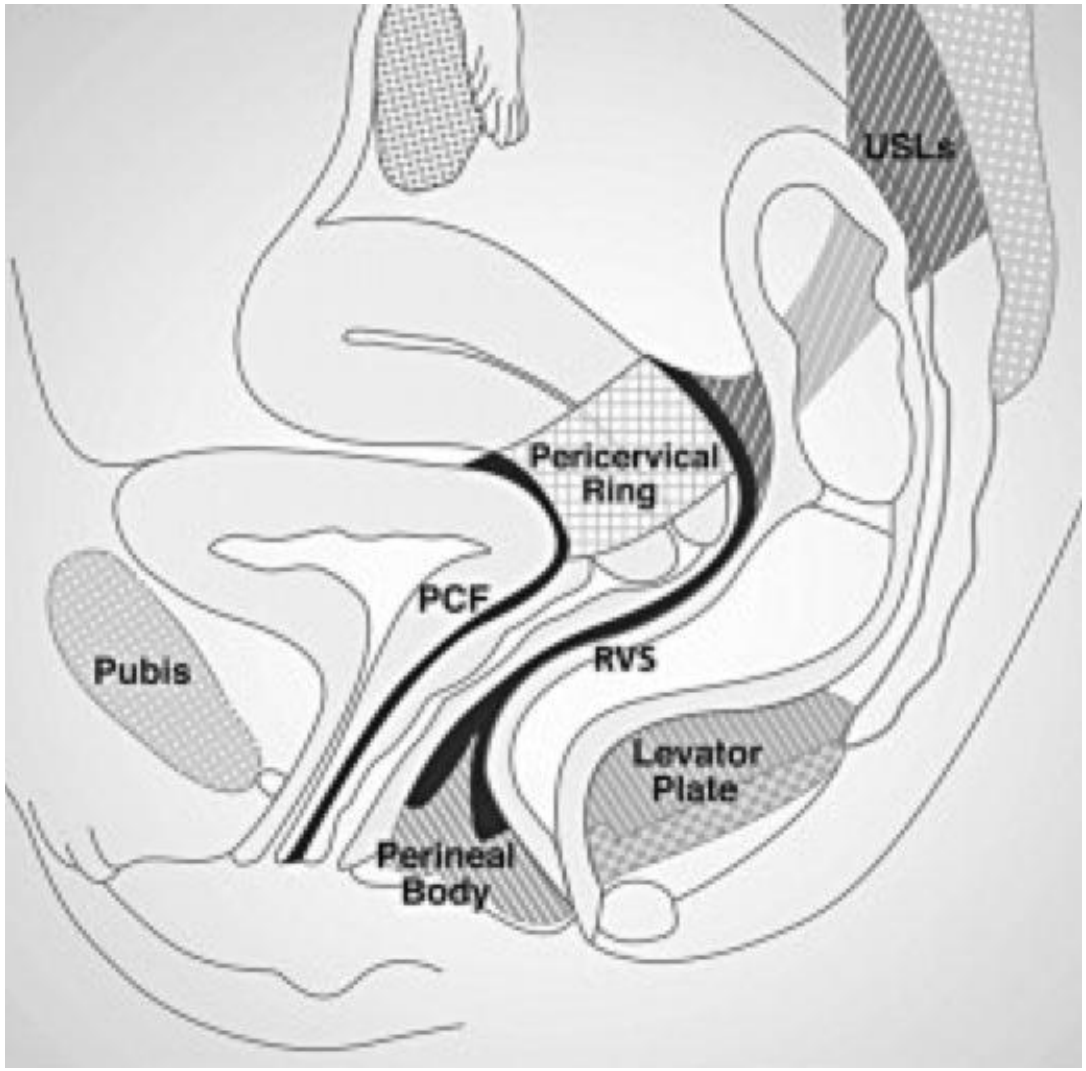
USLs
Pericervical Ring
PCF
RVS
Pubis
Levator Plate
Perineal Body

APPLIED SURGICAL ANATOMY

VAGINAL HYSTERECTOMY (VH)

- Pelvic organ prolapse is not corrected by VH **alone**.
- Limited evidence that VH has any advantage over uterine preservation.
- VH can be avoided unless there is other indication.

- McCall culdeplasty
- SSF
- uterosacral ligament suspension

VAGINAL VAULT PROLAPSE (VVP)

- A result of damage to cardinal - USLs.
- Incidence: 0.1 to 45% after hysterectomy.
- Associated with cystocele, rectocele, enterocele, or a combination.
- **Richter**: 72% of pts with VVP had other pelvic floor defects.
- **Cruickshank:** modified Mc Call culdoplasty is effective at preventing future apical defects (6% versus 30% incidence at 3 yrs).
- Reattach the apex to the SSL, iliococcygeous muscle or the USLs unilaterally or bilaterally.

The Ligaments

- Cardinal
  - Mesentery-like structure, originating at the level of internal iliac artery and reaching the lateral margins of the cervix and vagina.
  - Attached medially to the cervix and upper vagina, intermingling fibers with USL.
  - The origin is distributed to the pelvic wall around the origin of internal iliac vessels.

The Ligaments

- Uterosacral
  - The distal (cervical) section: the thickest portion. At the edge of the cervix and vagina, it is fused with the CL. Dense connective tissue containing small blood vessels and small branches of the hypogastric plexus.
  - The intermediate section 5 cm in length and 5mm in thickness, it thins out gradually as it progresses posteriorly.
  - The proximal (sacral) section 5.5cm long but variable in thickness and appearance. Thin sheet of connective tissue with no clear fibrillar appearance.

Neurourology and Urodynamics 33:380–386 (2014)

A Historical Perspective and Evolution of Our Knowledge on the Cardinal Ligament

George Iancu and Stergios K. Doumouchtsis

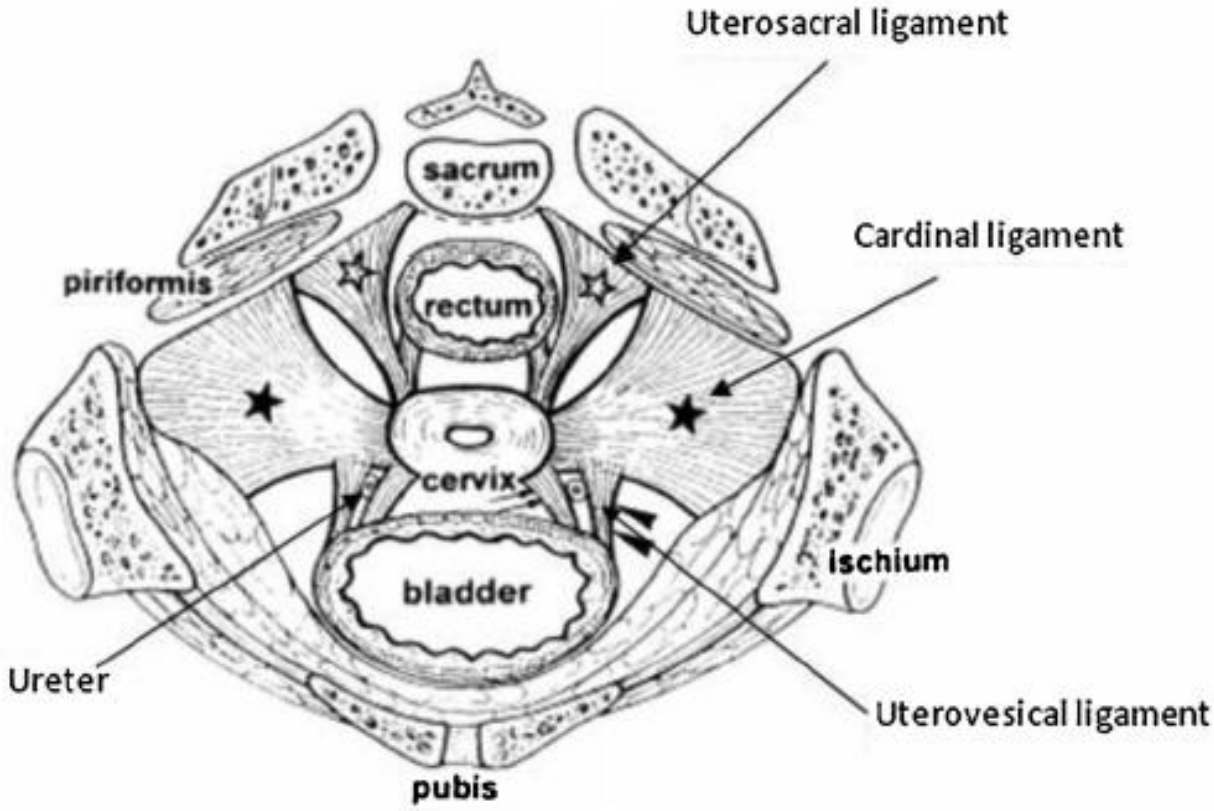

Neurourology and Urodynamics 33:380–386 (2014)

A Historical Perspective and Evolution of Our Knowledge on the Cardinal Ligament

George Iancu and Stergios K. Doumouchtsis

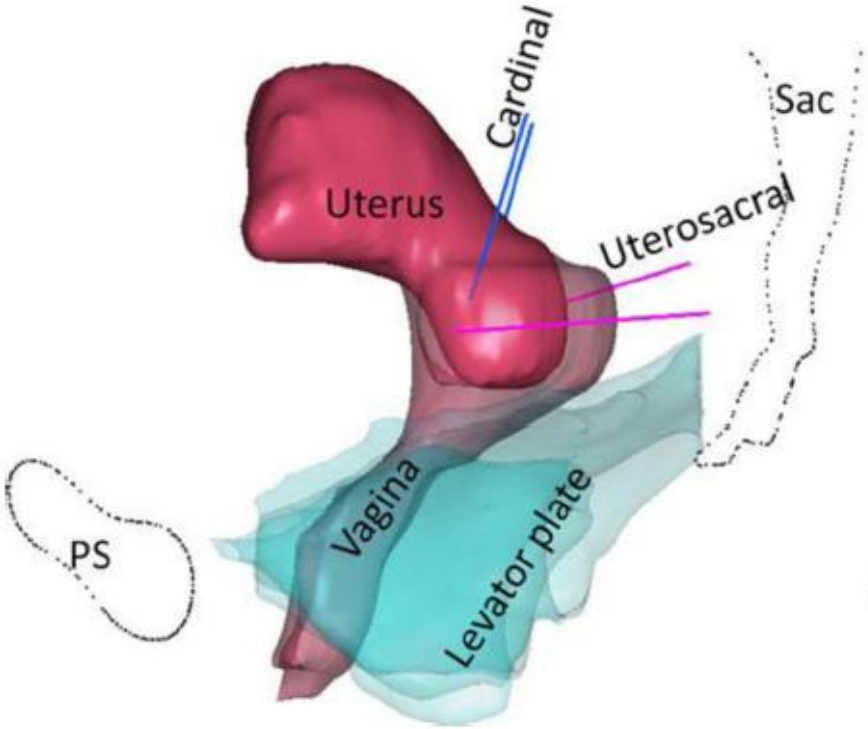

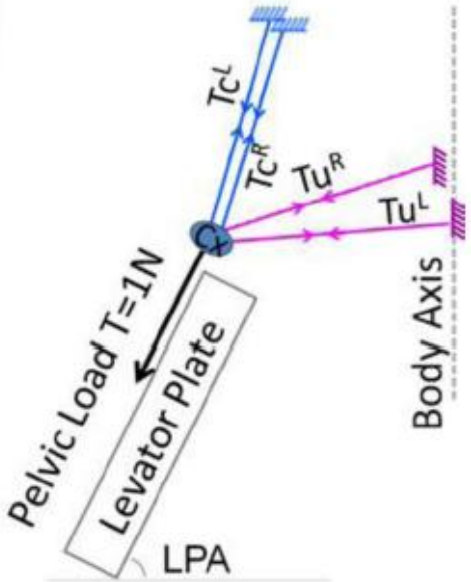

Lines of action of loading forces with corresponding tension in the ligaments

Chan et al 2012

Uterosacral and Cardinal Ligaments

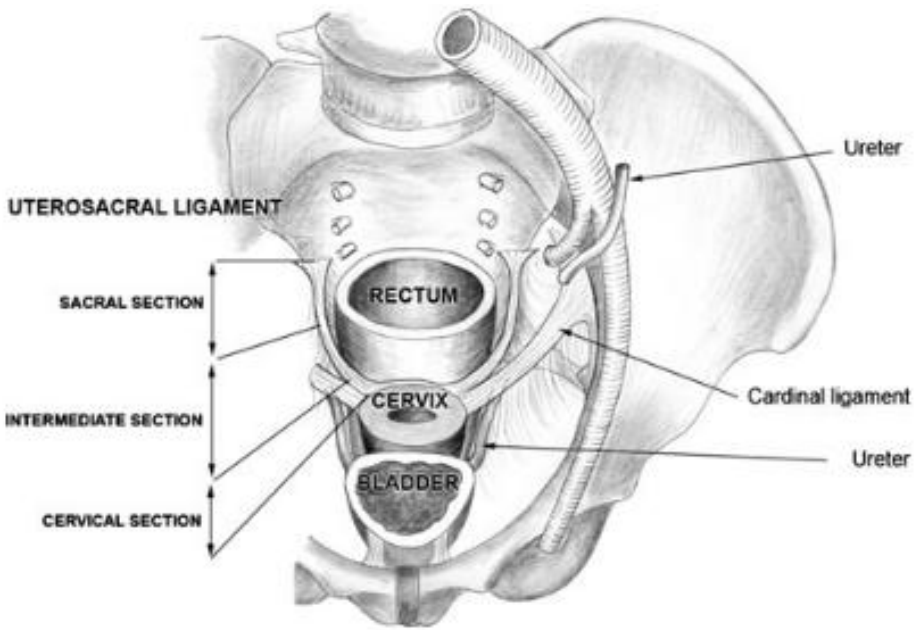

- The thick (5–20 mm) **distal section**, attached to cervix and upper vagina, is confluent laterally with the cardinal ligament.
- The **proximal section** is diffuse in attachment and generally thinner.
- The relatively unattached **intermediate section** is wide, and thick, well defined when placed under tension, more than 2 cm from the ureter.

Vu et al 2010

High Uterosacral Ligament Suspension

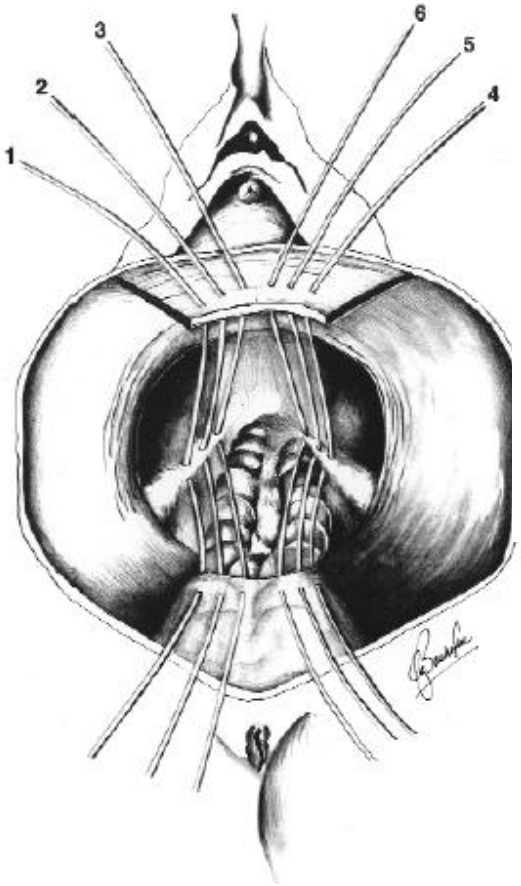

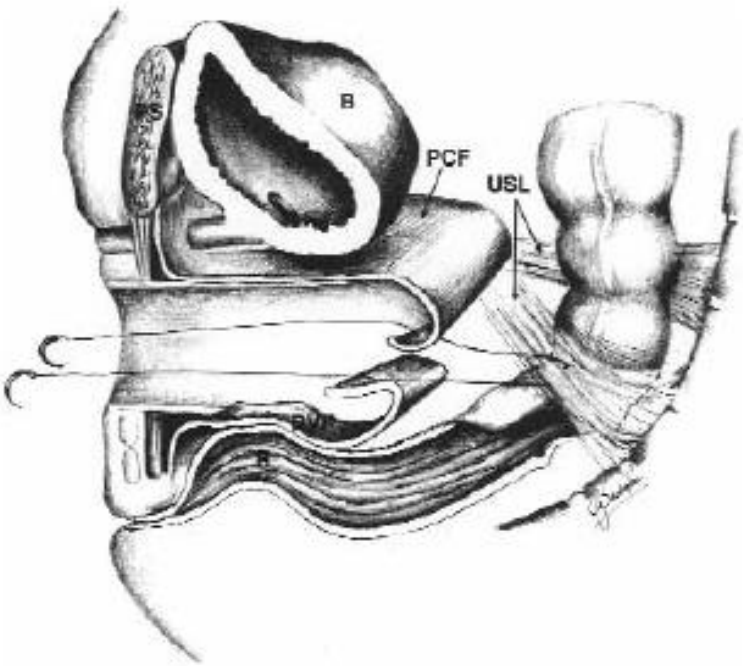

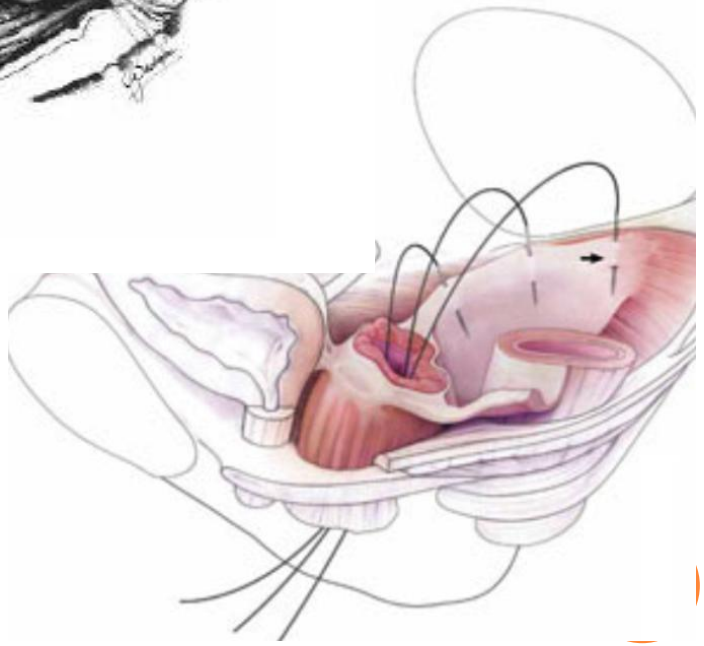

Shull et al (2000), Am J Obstet Gynecol 183, 6

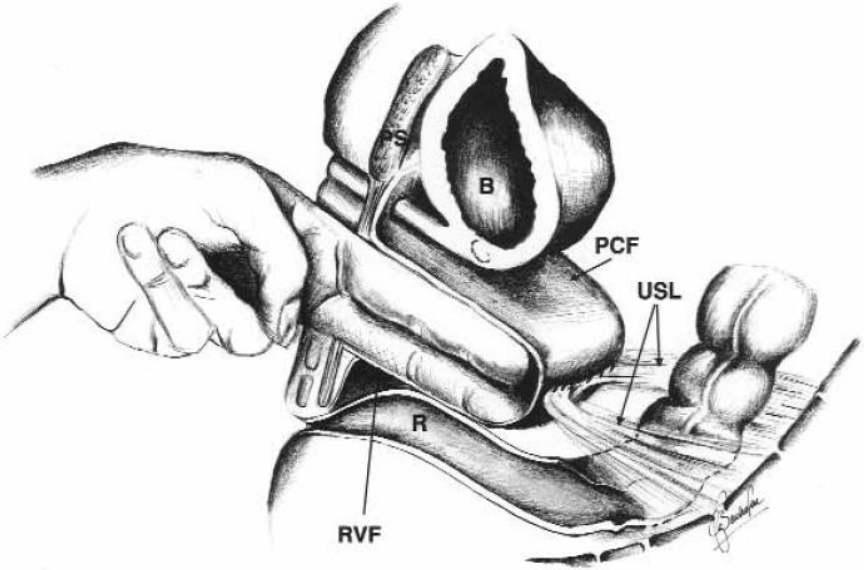

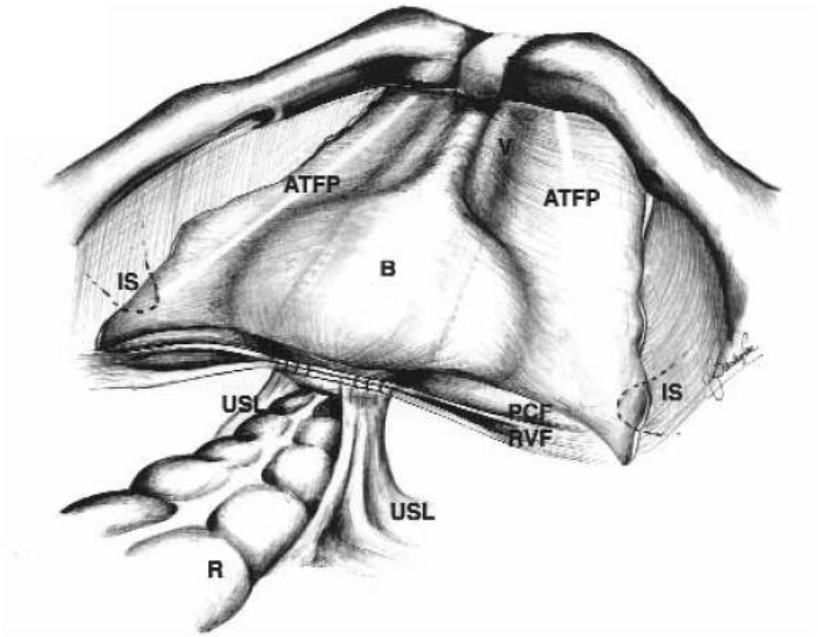

Shull et al (2000), Am J Obstet Gynecol 183, 6

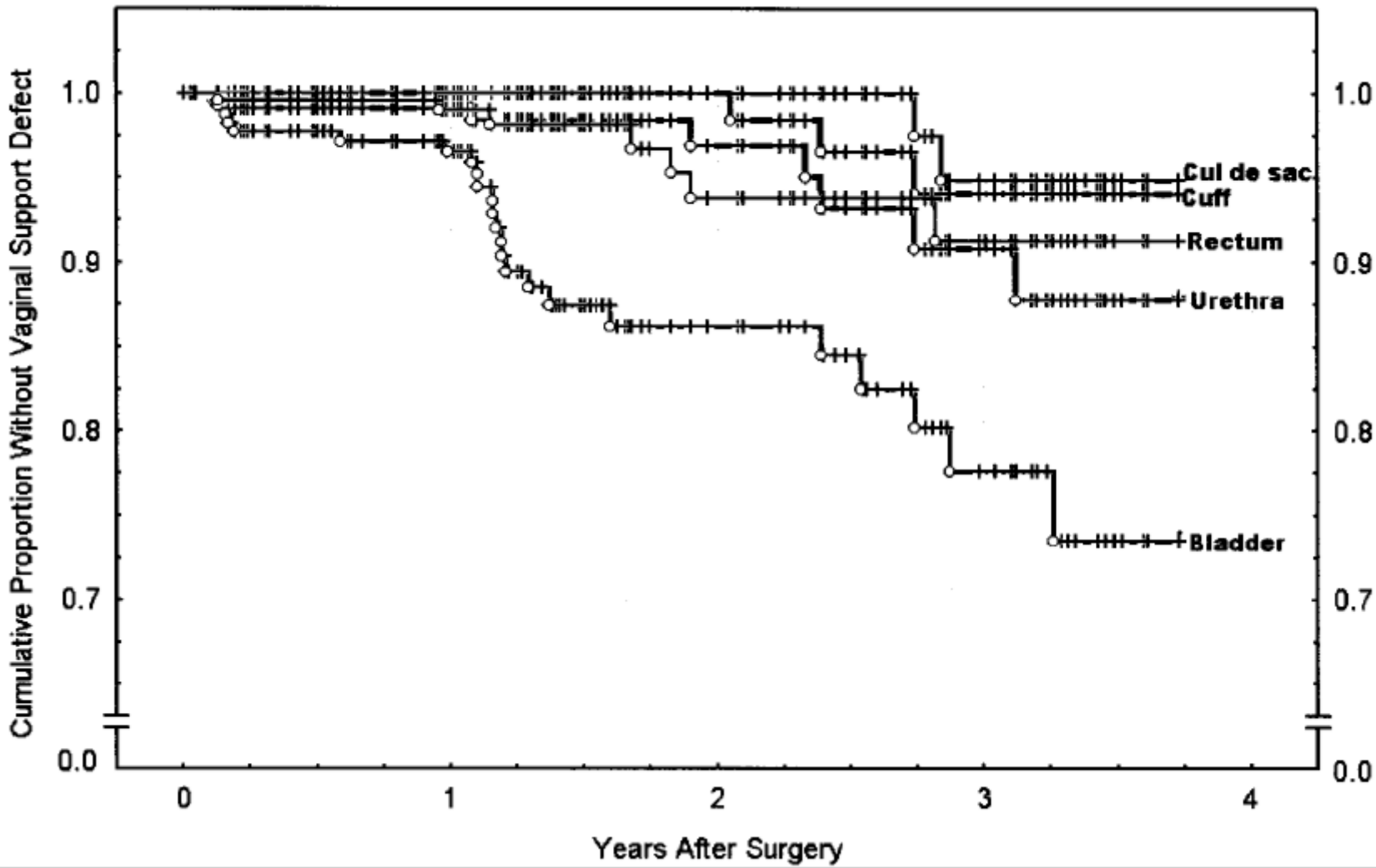

Shull et al (2000), Am J Obstet Gynecol 183, 6

Modified HUSLS

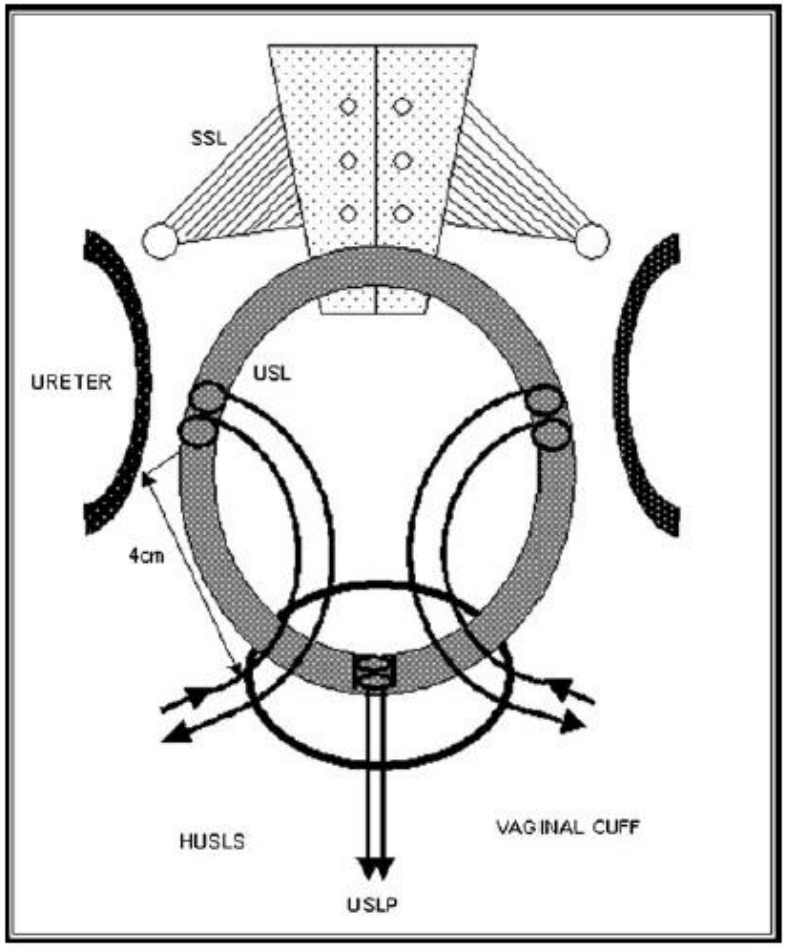

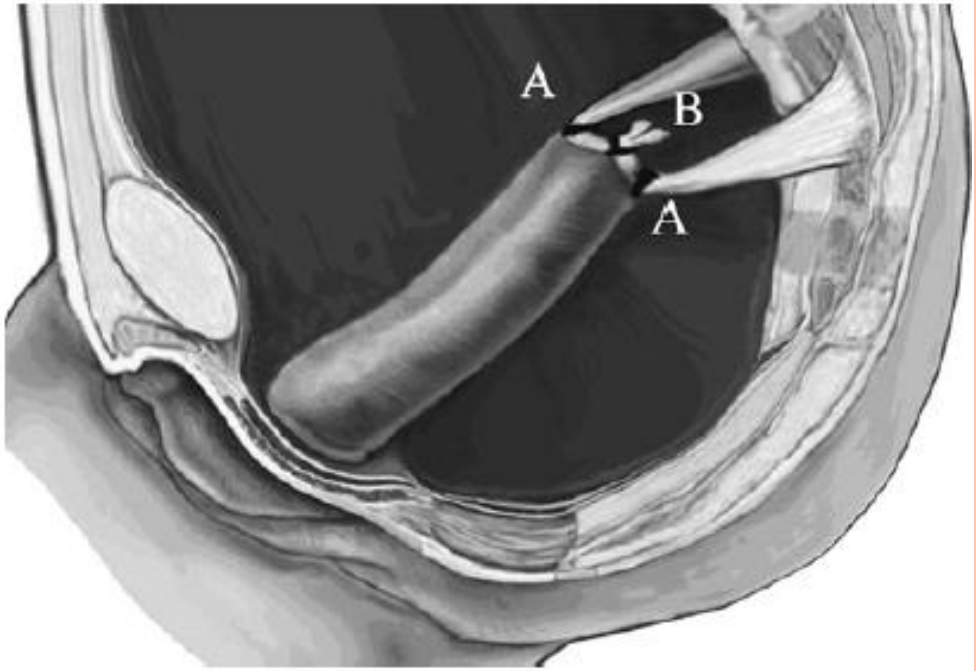

Doumouchtsis Int Urogynecol J. 2011 May;22(5):577-84

Modified HUSLS

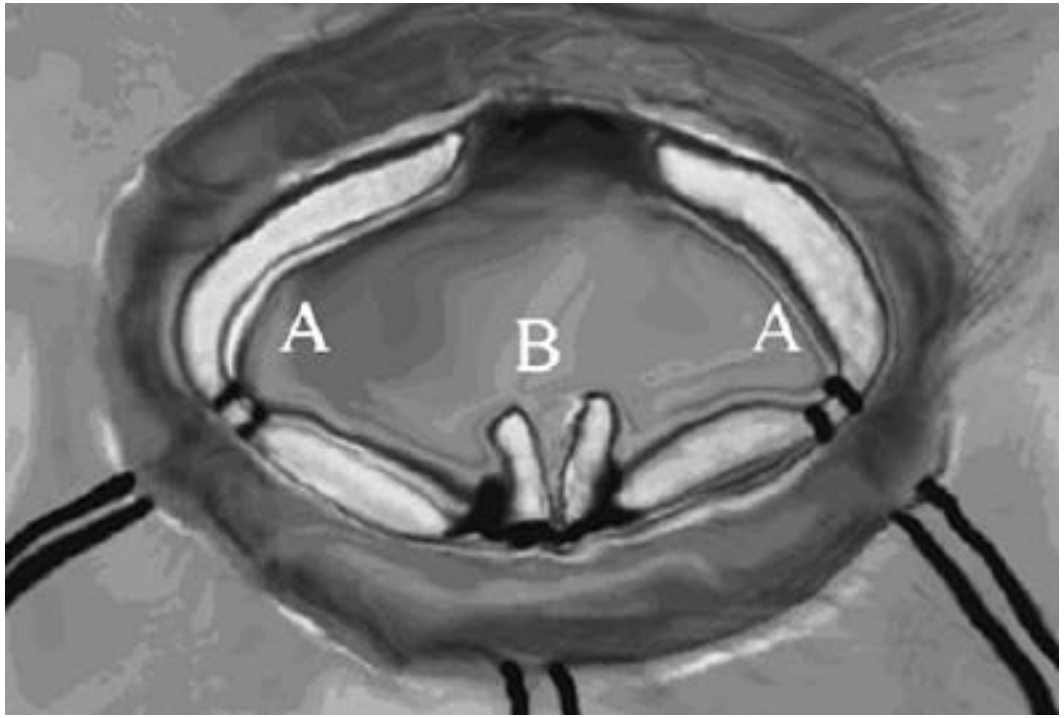

Doumouchtsis Int Urogynecol J. 2011 May;22(5):577-84

The Sacrospinous Ligament

- Flat triangular ligament
- Apex attaches to the ischial spine
- Base attaches to the lateral surface of the sacrum and coccyx
- The tendinous posterior part of the ischiococcygeus muscle

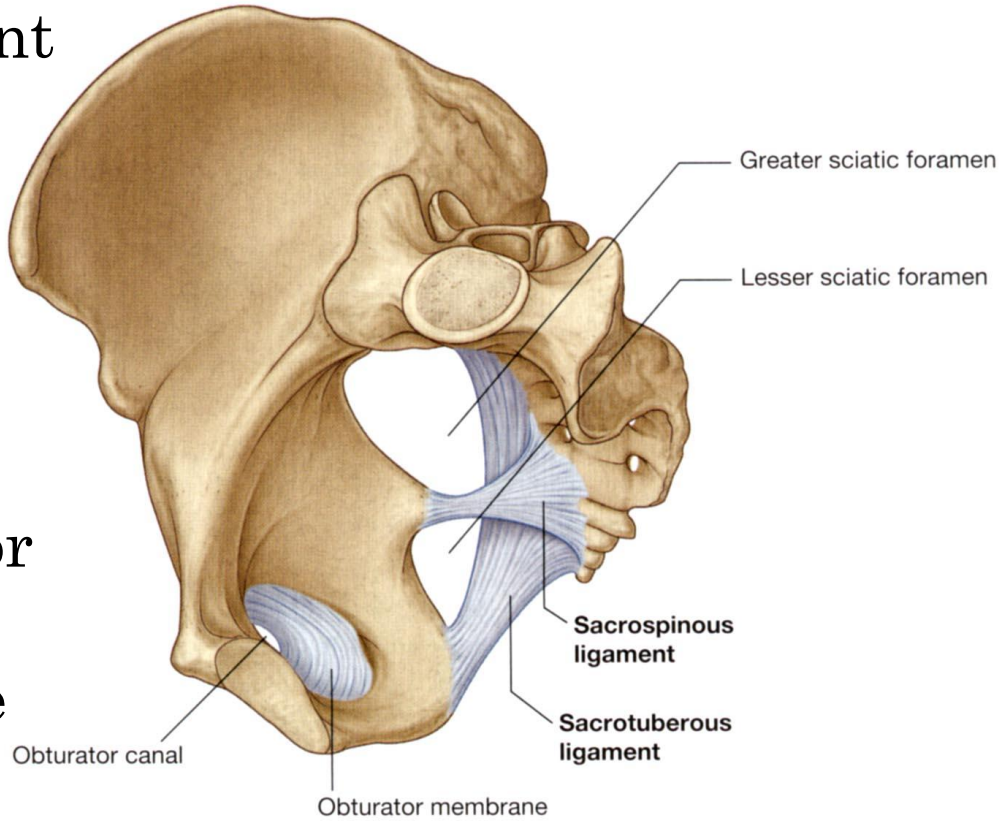

Sacrospinous Ligament Fixation

- First described by Sederl in 1958
- Popularized by Richter and Albright in Europe, Randall and Nichols in United States
- Unilateral or bilateral
- Subjective success rates 67 - 97 %

- Complications:
  - Haemorrhage
  - Injury to pelvic organs (rectum & bladder - 0.8%)
  - Gluteal pain (up to 3%)
  - Perineal paraesthesia

Vaginal Fornix

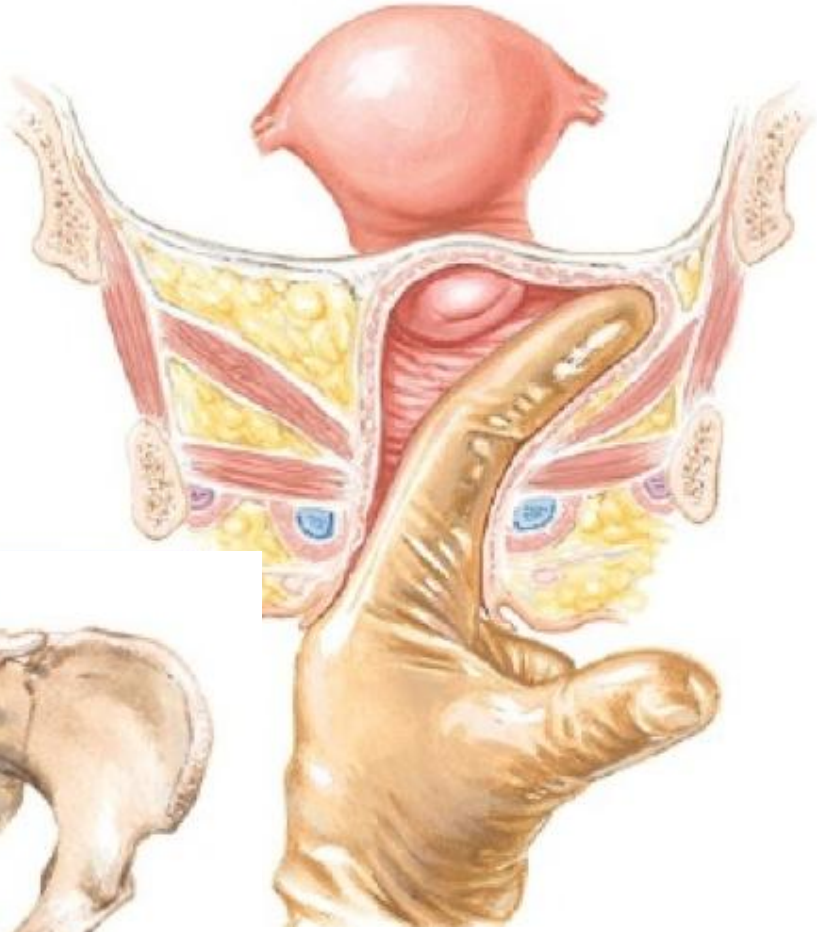

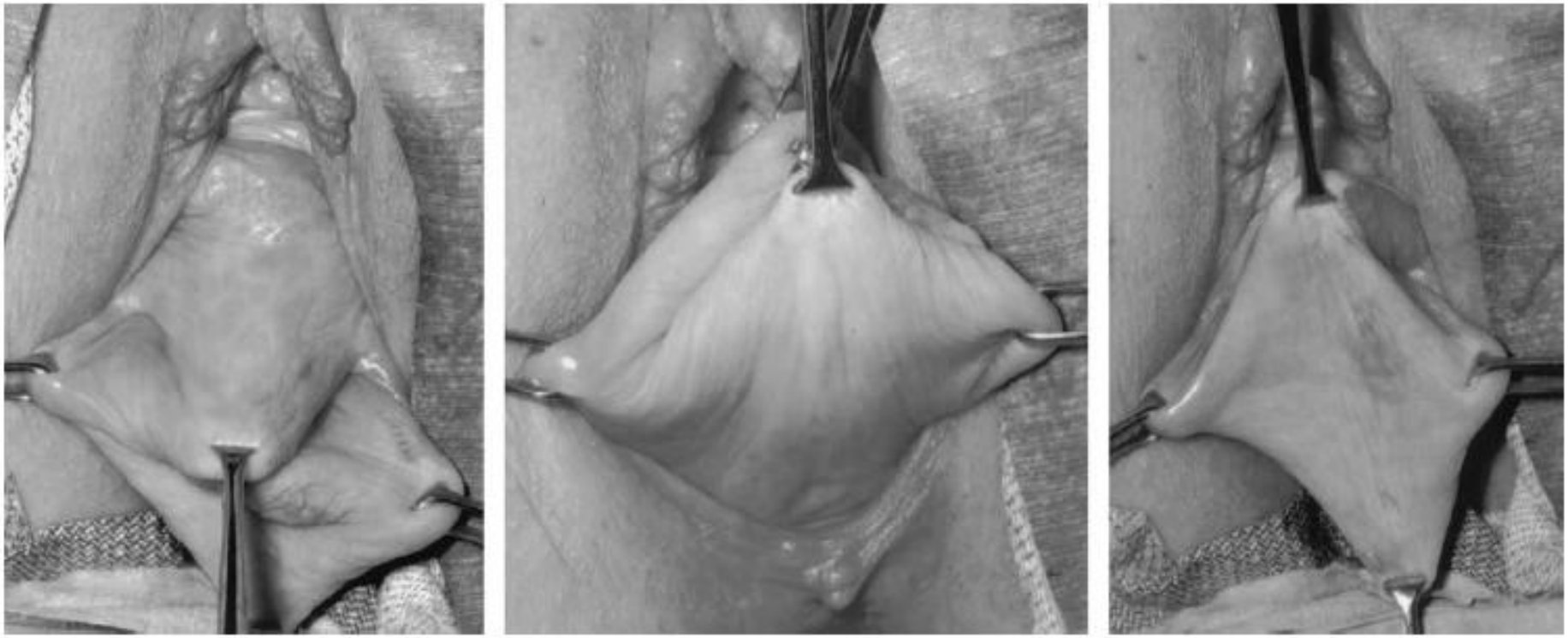

Kearney. Apex Location at Sacrospinous Suspension. Obstet Gynecol 2003.

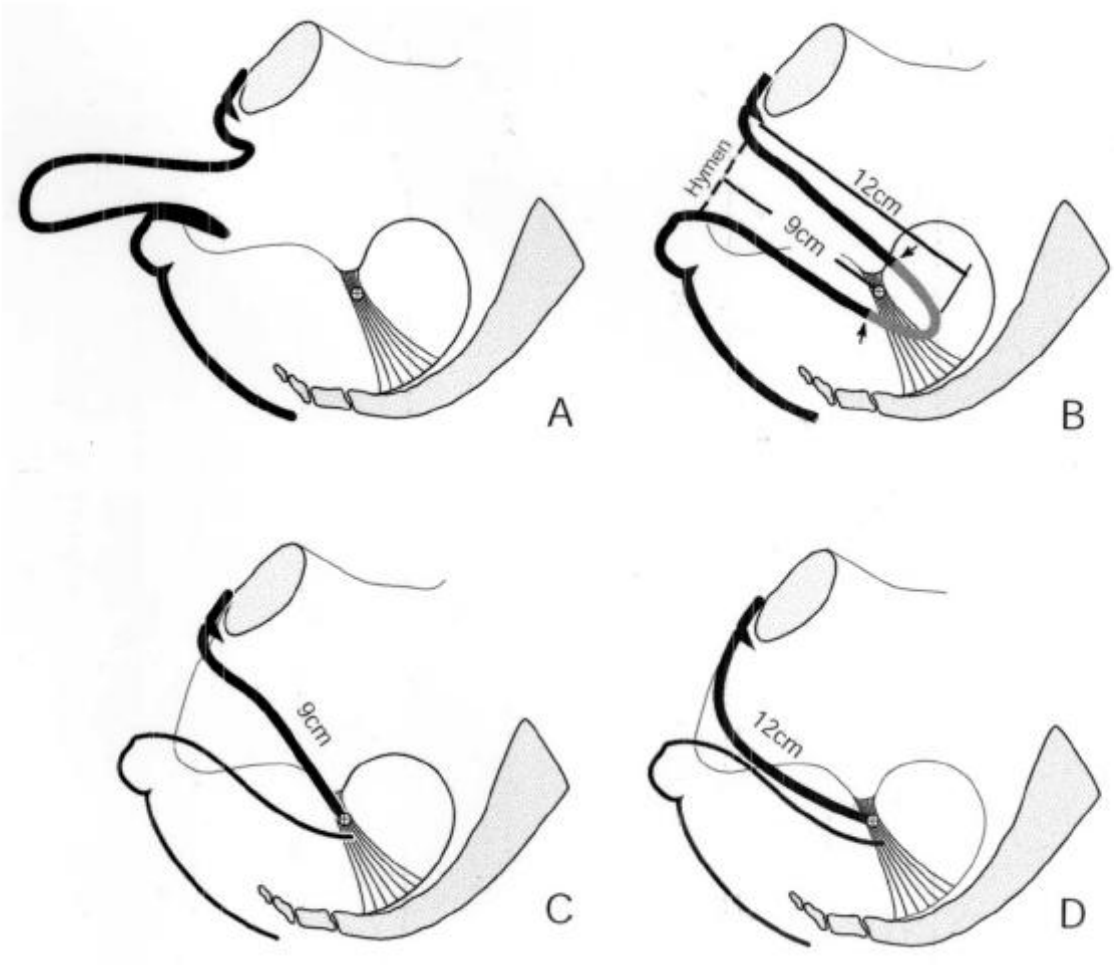

Kearney. Apex Location at Sacrospinous Suspension. Obstet Gynecol 2003.

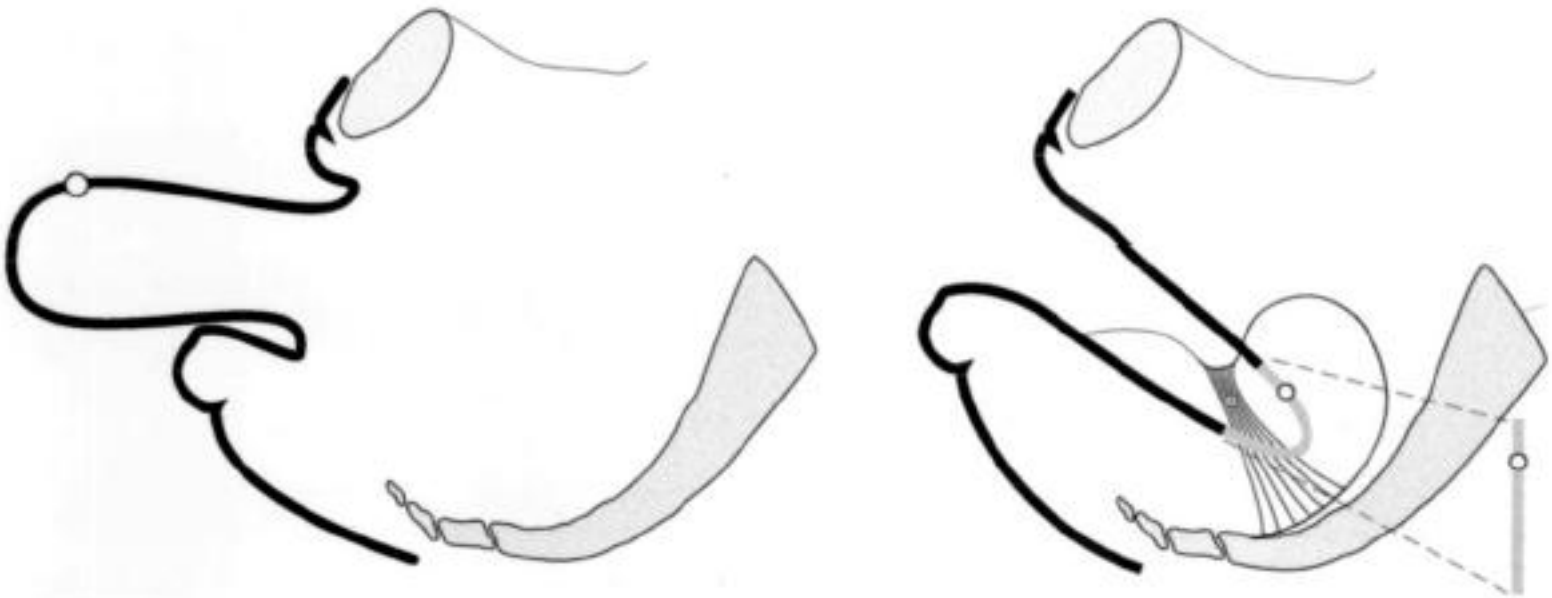

Kearney. Apex Location at Sacrospinous Suspension. Obstet Gynecol 2003.

Access to SSL

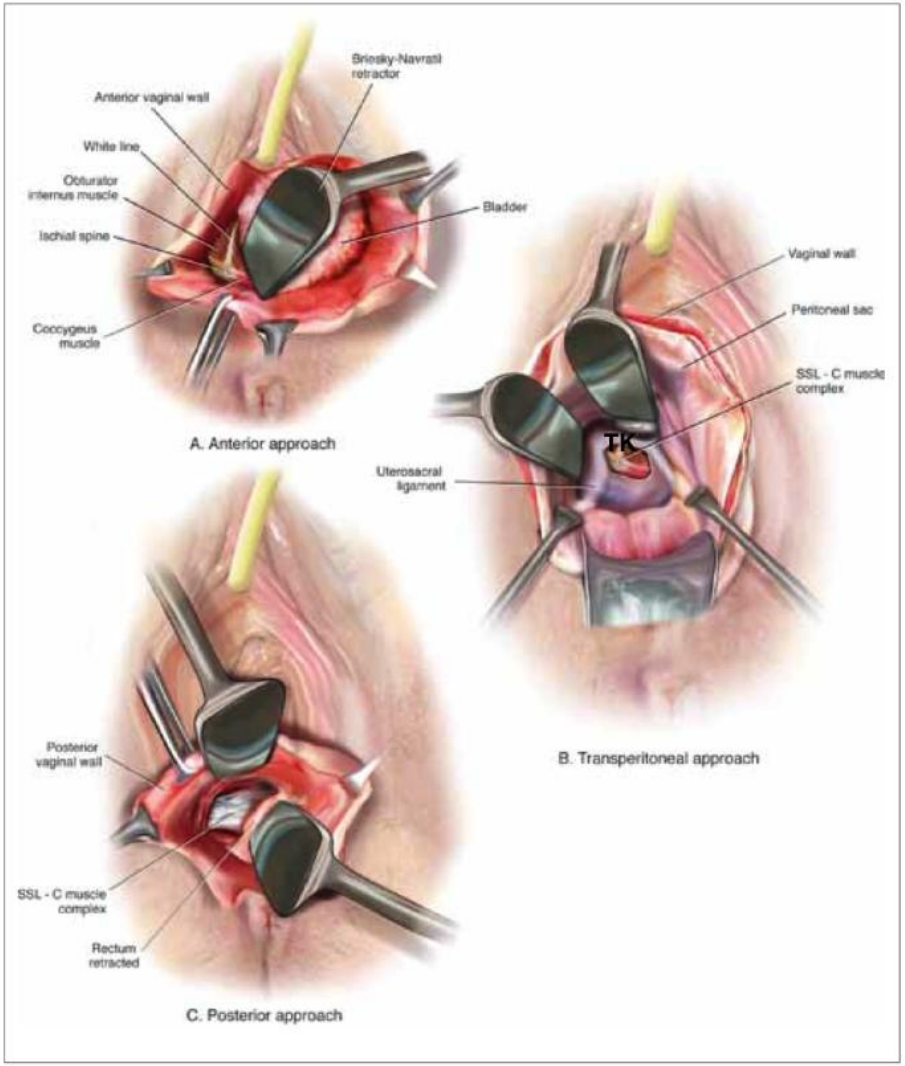

The sacrospinous ligament can be palpated and exposed along any one of three approaches: anterior paravaginally (**A**), transperitoneally (**B**), and posterior pararectally (**C**).

De Tayrac, IUJ 2010

Access to SSL Deschamps

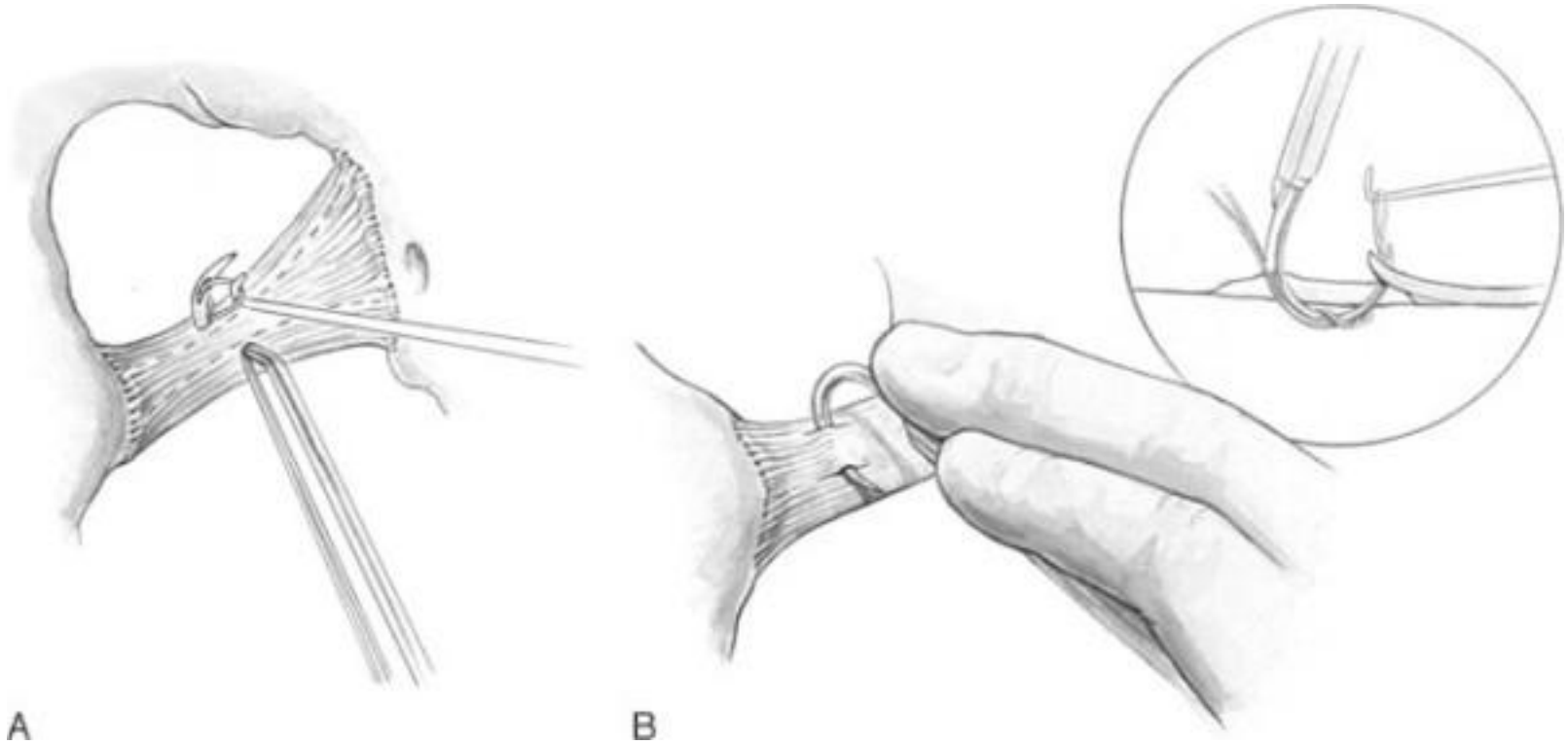

Walters: Urogynecology and Reconstructive Pelvic Surgery, 3rd Ed.

Anterior Sacrospinous Suspension

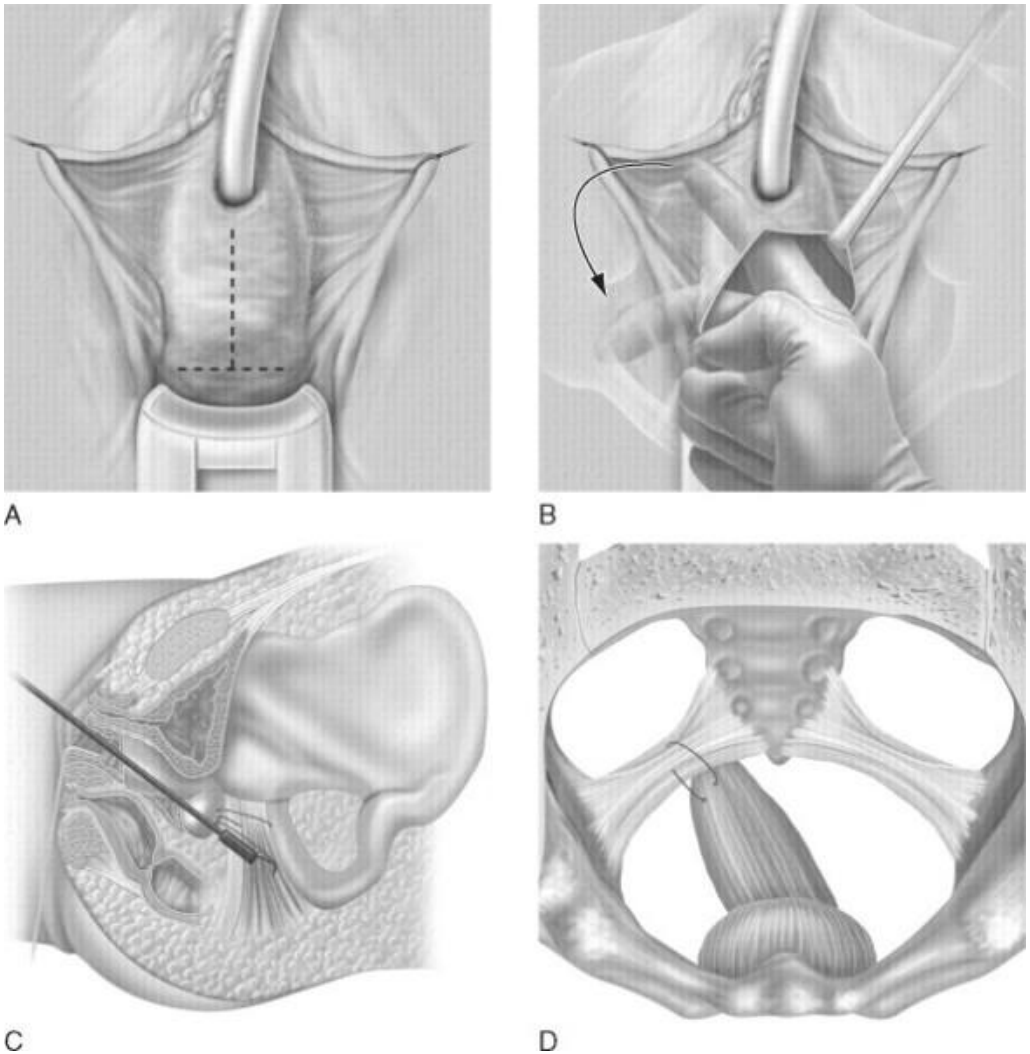

Raz Female Urology, 3rd Ed

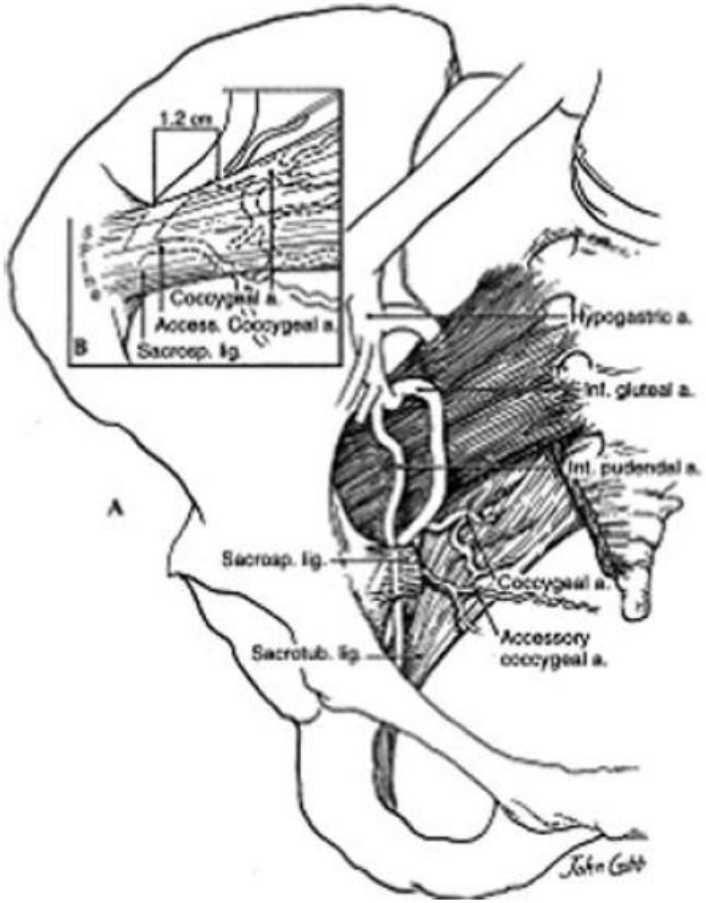

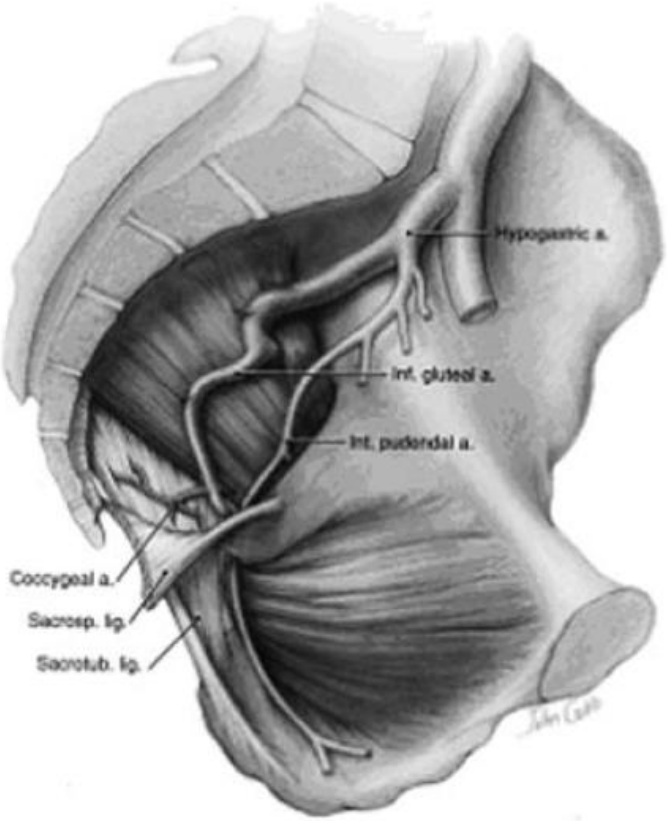

Morgan et al 2010

Anatomic Variations

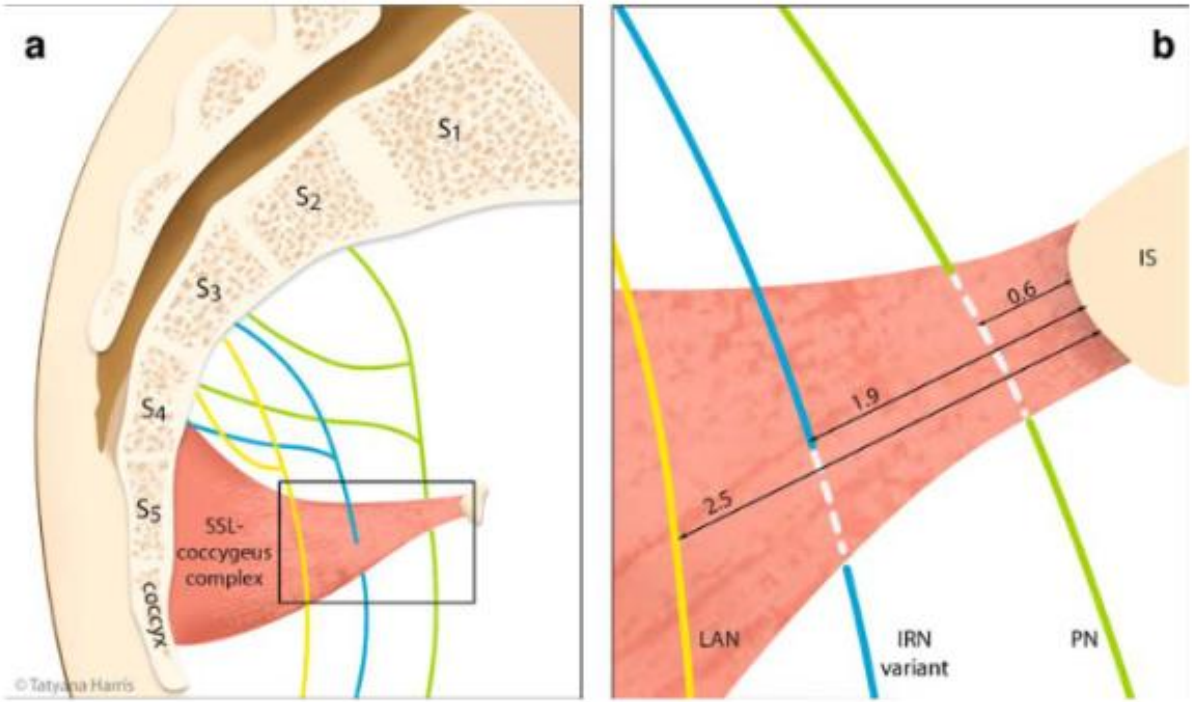

Fig. 4 Schematic diagram illustrating the nerve distribution in the region of the coccygeus muscle sacrospinous ligament complex (SSL–coccygeus complex) in cadavers with an inferior rectal nerve variant, in the left hemipelvis. **a** The levator ani nerve (shown in *yellow*) originates from the sacral foraminas S3 and/or S4 and crosses anterior to the SSL–coccygeus complex. Lateral to the levator ani nerve, the inferior rectal nerve variant (shown in blue) originates from the S3 and/or S4 nerve roots and pierces the midpoint of the SSL–coccygeus complex to enter the ischio-rectal fossa. The pudendal nerve (shown in *green*) originates from the S2, S3, and S4 nerve roots, and in most cadavers, it passes posterior to the *SSL* and medial the ischial spine. **b** Magnified view of the nerves in diagram in (**a**). The nerves shown in (**a**), the levator ani nerve (LAN), the inferior rectal nerve variant (IRN variant), and the pudendal nerve (PN) are shown passing medial to the ischial spine (IS) at the mean distances of 2.5, 1.9, and 0.6 cm, respectively

Lazarou et al 2008

Vaginal Configuration (MRI Data)

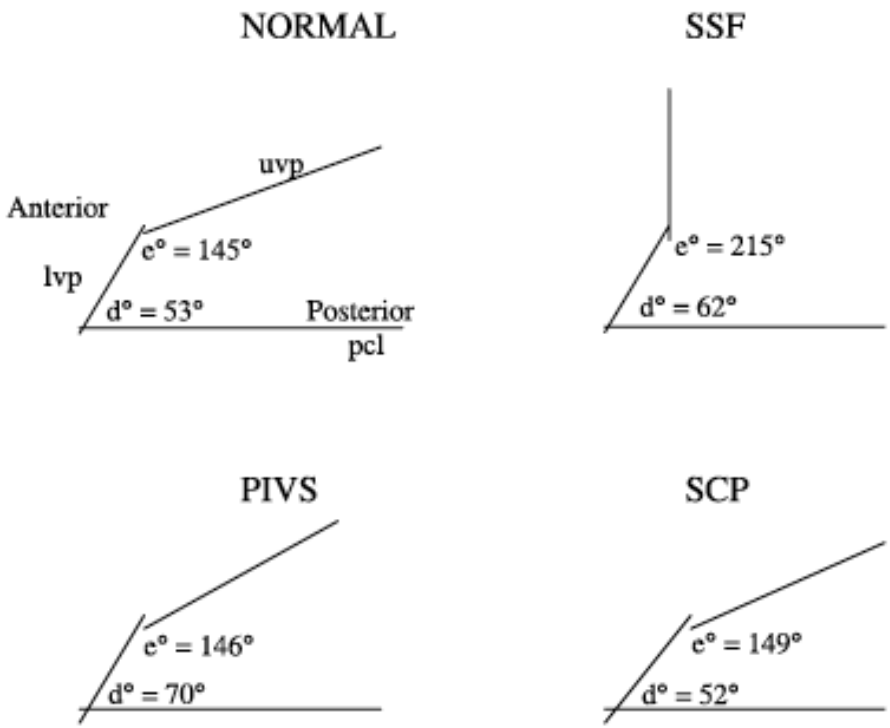

Figure 2 Schematic diagrams showing the vaginal configurations (using mean angles) of normal subjects and after each procedure. d°, angle between pubococcygeal line and lower vaginal plane; e°, angle between lower and upper vaginal planes; UVP, upper vaginal plane; LVP, lower vaginal plane; PCL, pubococcygeal line; PIVS, posterior intravaginal slingplasty; SCP, sacrocolpopexy; SSF, sacrospinous fixation.

Rane et al 2004

Sacrocolpopexy: Vaginal Axis and Mesh Fixation

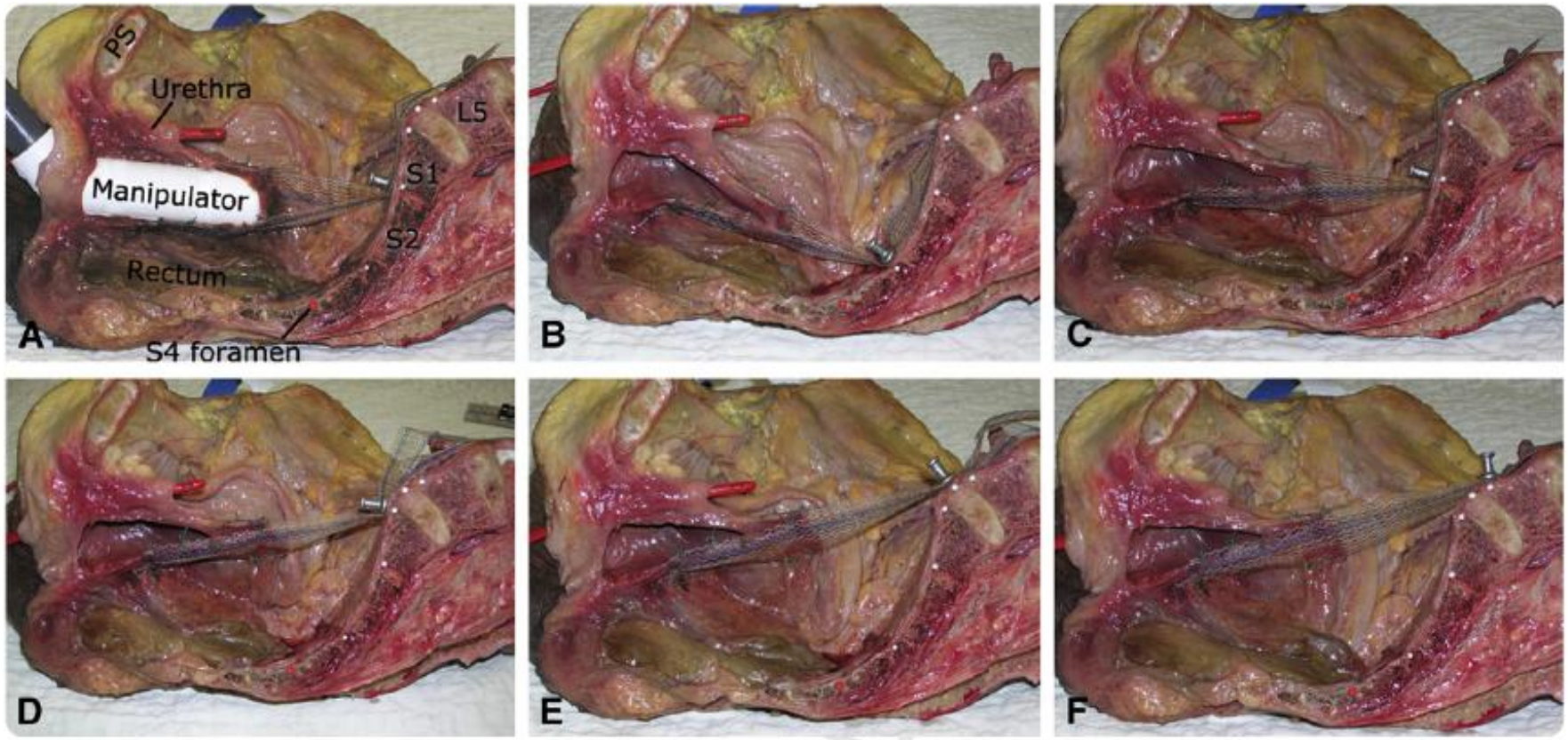

A, Apex of vagina was directed to the point of sacral fixation with a manipulator and both strips of mesh were attached sequentially at the 5 study points marked with a white metal pin. These included **B,** the lower portion of S2; **C,** lower portion of S1; **D,** sacral promontory; **E,** mid portion of L5-S1 disc; and **F,** lower portion of L5.

L5, fifth lumbar vertebra; *S1*, first sacral vertebra; *S2*, second sacral vertebra.

Balgobin. Sacrocolpopexy vaginal axis and sacral attachment site. Am J Obstet Gynecol 2013.

Neurourology and Urodynamics

Management of Apical Compartment Prolapse (Uterine and Vault Prolapse): A FIGO Working Group Report

Cornelia Betschart,[1*] Mauro Cervigni,[2] Oscar Contreras Ortiz,[3] Stergios K. Doumouchtsis,[4] Masayasu Koyama,[5] Carlos Medina,[6] Jorge Milhem Haddad,[7] Filippo la Torre,[8] and Giuliano Zanni[9]

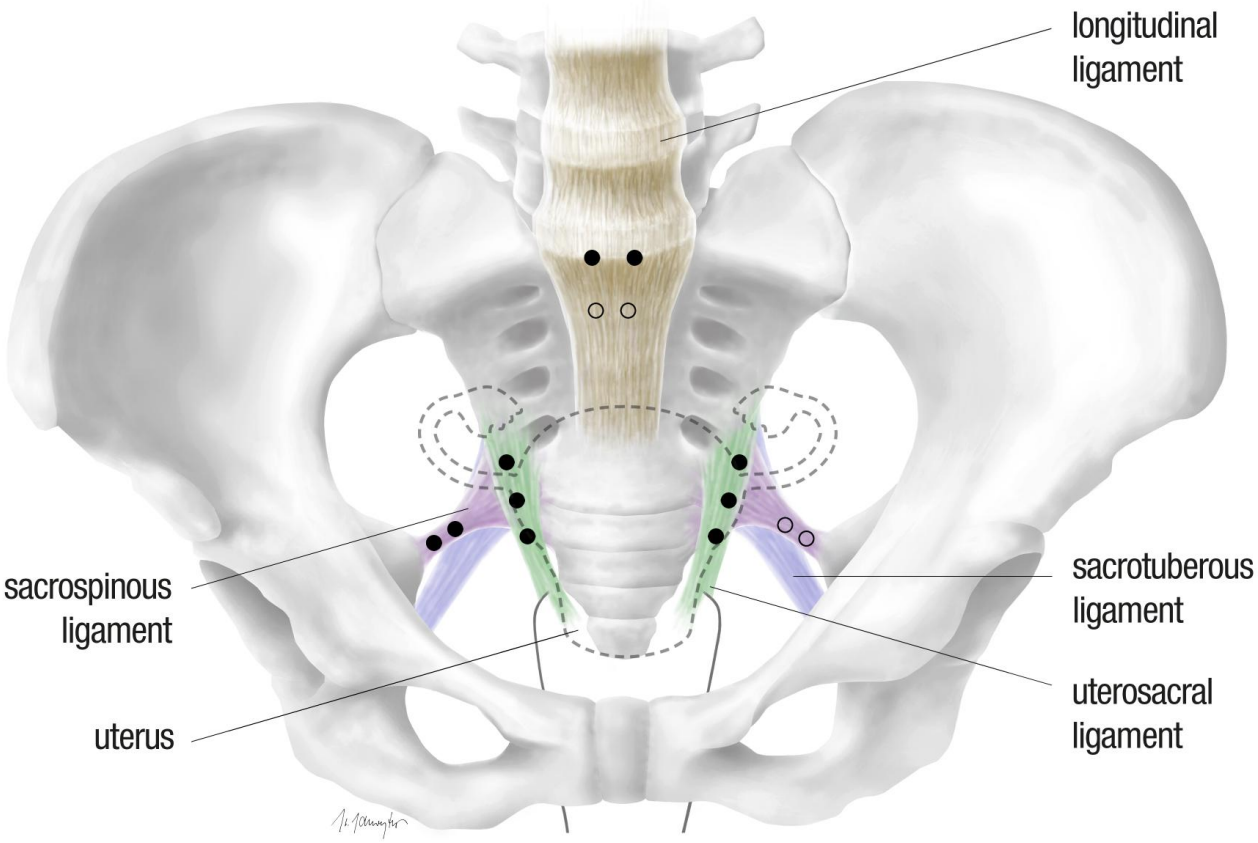

Anterior Vaginal Wall

- Downward translation
- Cupping
- Distal rotation

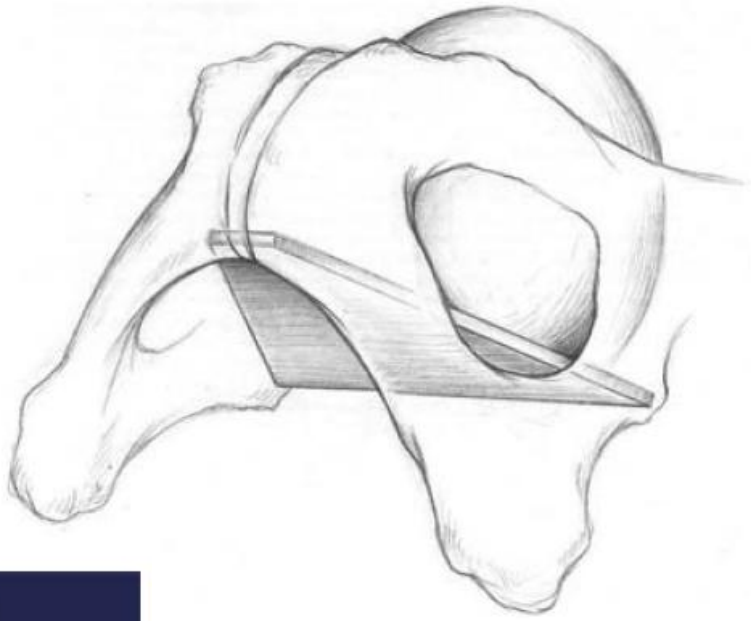

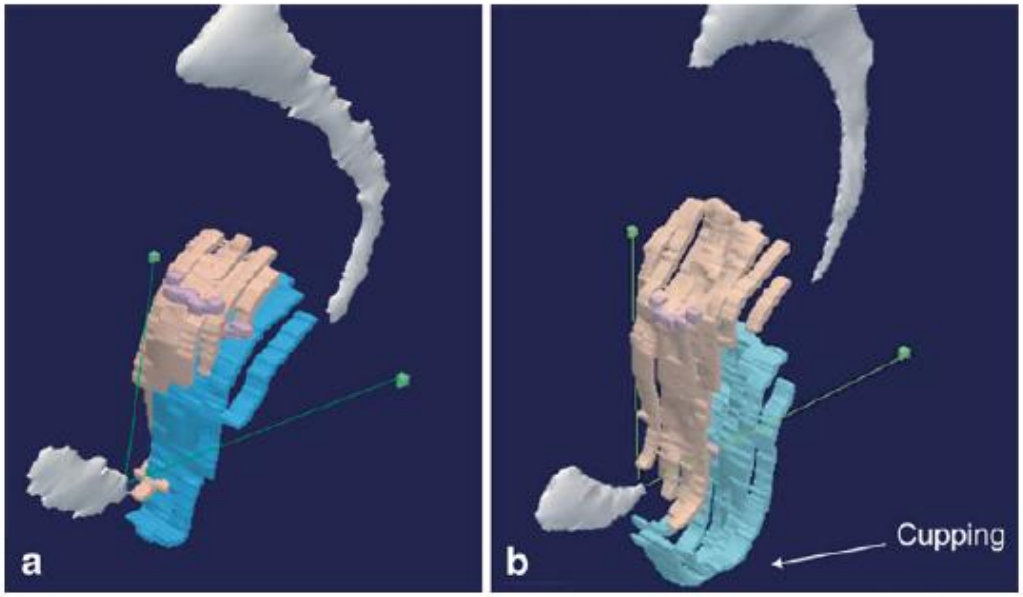

Larson et al 2010

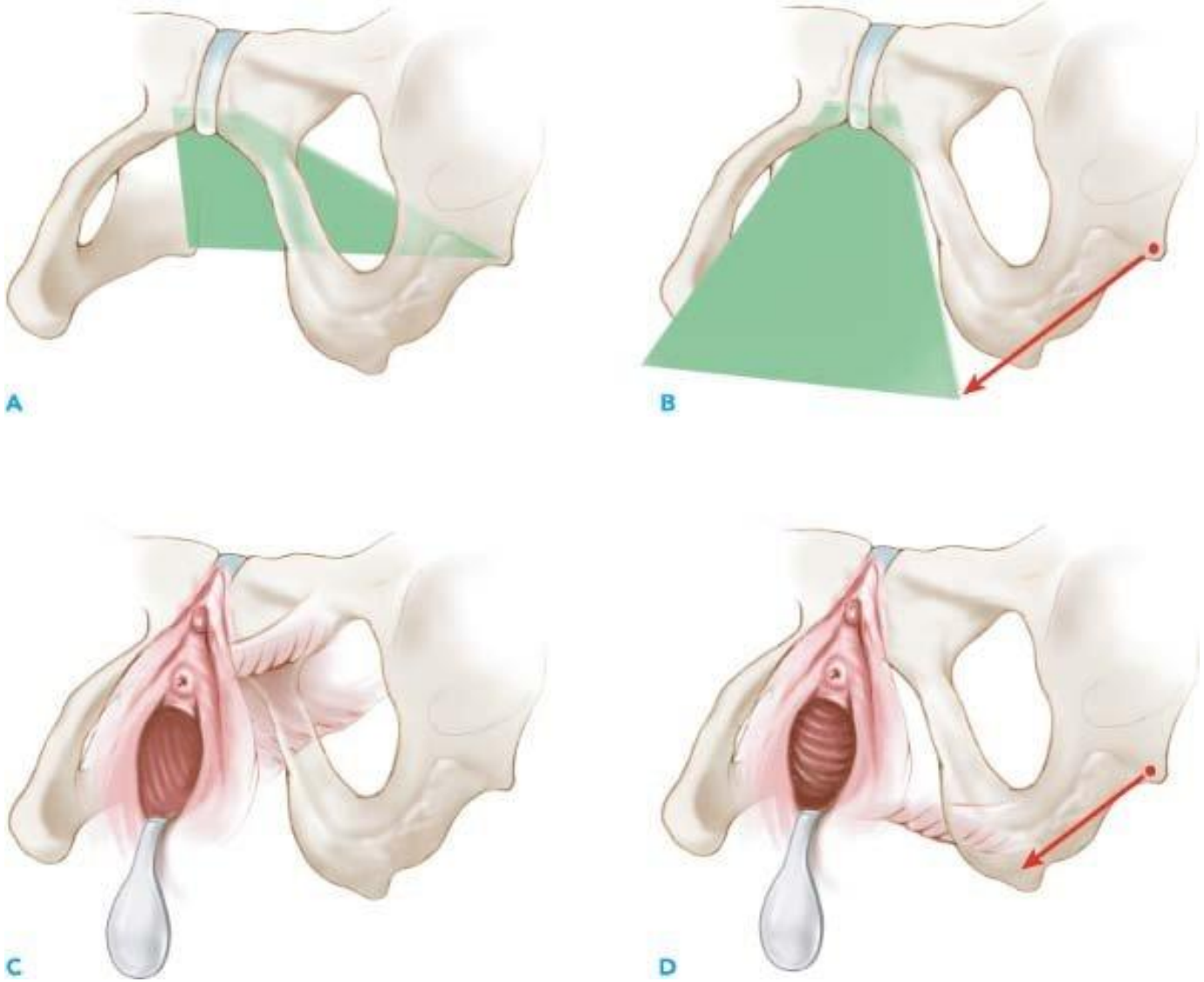

Berek & Novak Gynaecology

Defects

Midline

Paravaginal

Transverse

Cephalad

FIGURE 2. A transverse defect with loss of the anterior fornix.

FIGURE 3. A cephalad defect with loss of apical attachment at the level of the ischial spine.

Brincat et al 2010

Anterior Colporrhaphy

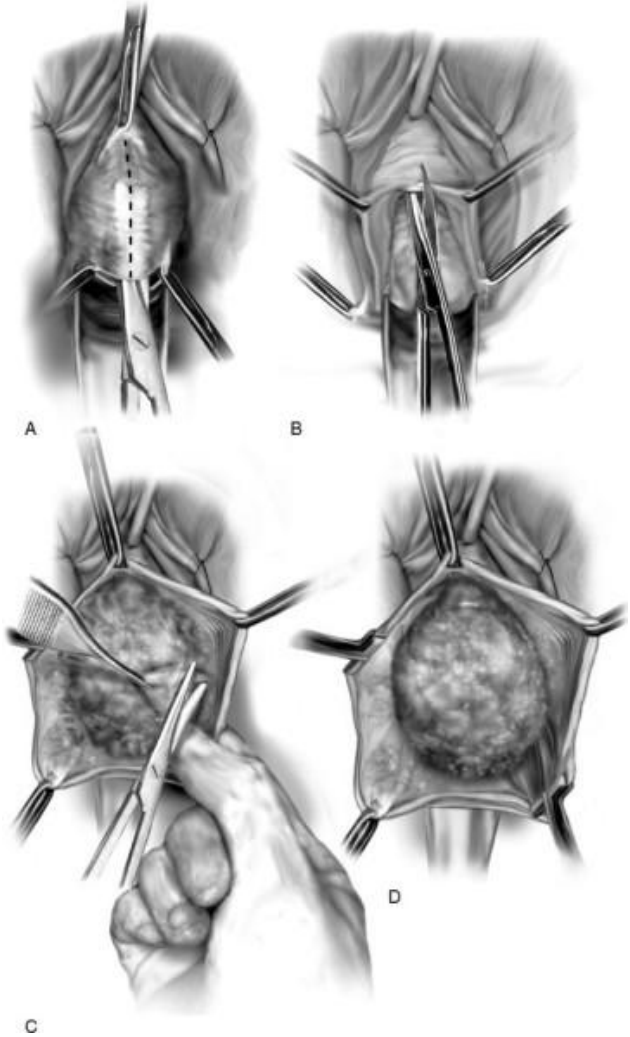

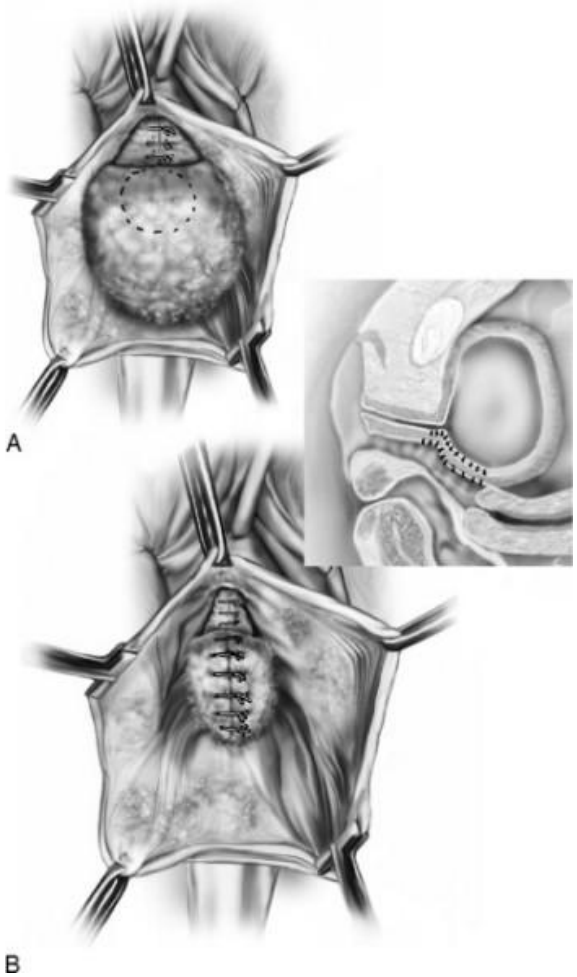

Walters: Urogynecology and Reconstructive Pelvic Surgery, 3rd Ed.

Posterior Compartment

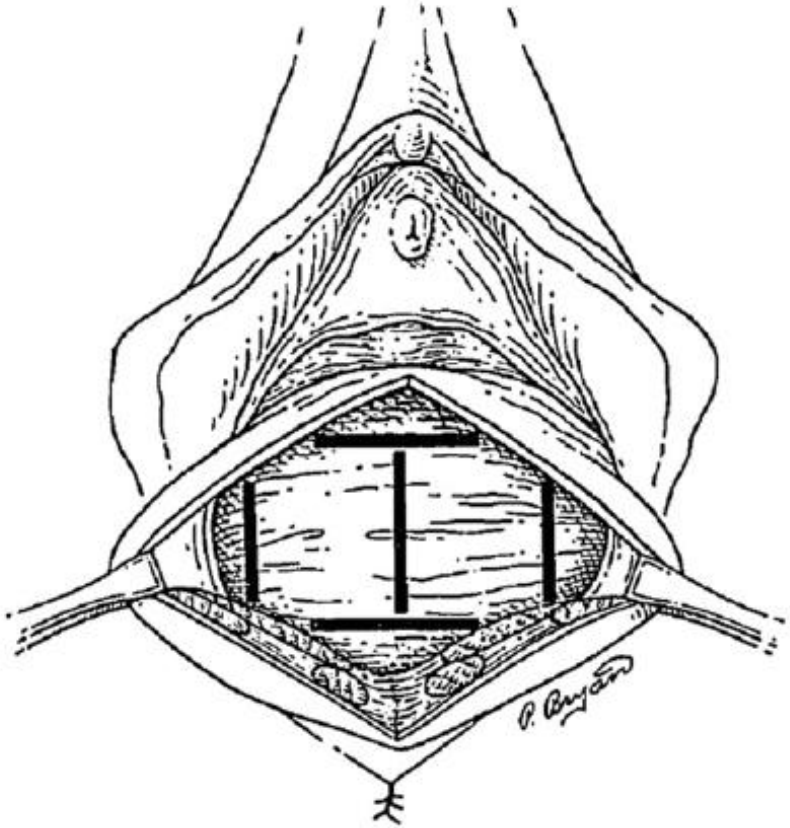

- The various locations of breaks in the rectovaginal septum.

Richardson 2012

Concept diagram showing mechanics of support

A. Closure of pelvic floor by puborectalis muscle (large arrow). Increases in abdominal pressure result in balanced pressure on anterior and posterior vaginal walls (arrows). Caudally, there is no balancing pressure, and force results (dashed arrow) that must be resisted by the fibers of the perineal membrane (shaded area) of perineal body.

B, Absence of levator-mediated closure of pelvic floor. Increases in rectal pressure are unopposed (arrow).

C, Level II supports oppose force shown in B(dashed arrow) by their upward dorsal tension (arrows attached to posterior vaginal wall and endopelvic fascia).

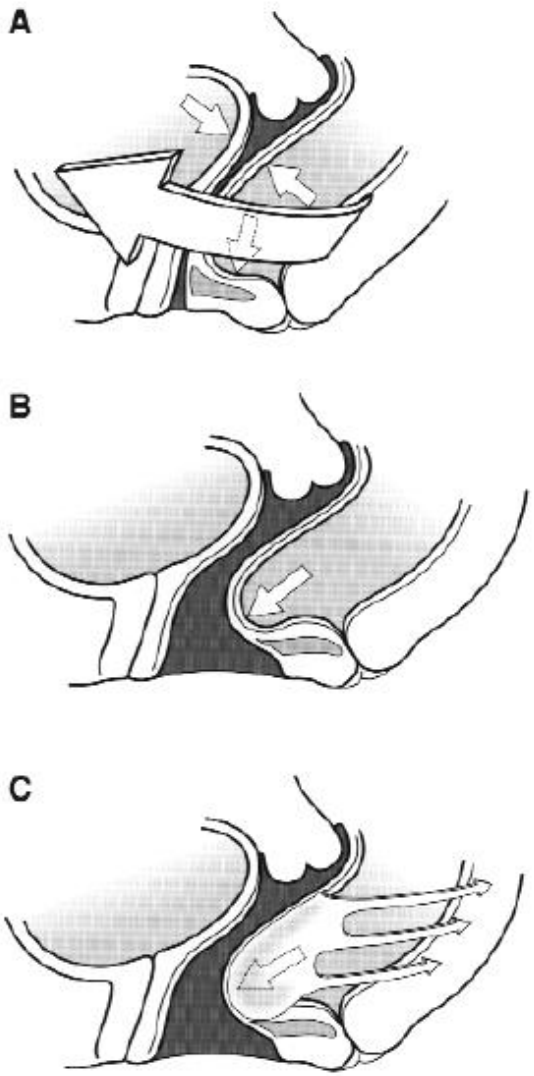

DeLancey 1999

Perineal Membrane and Perineal Body

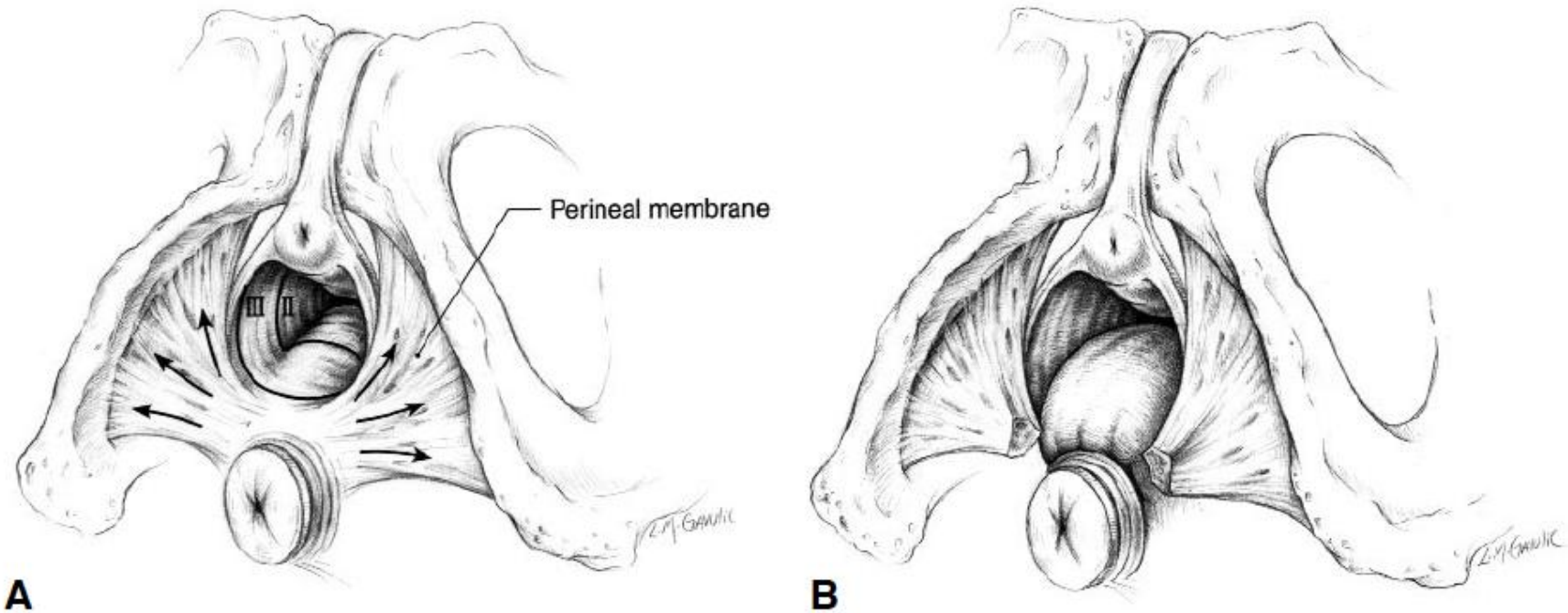

Peripheral attachments of perineal membrane to ischiopubic rami and direction of tension on fibers uniting through perineal body (arrows). B, These fibers have been transected, exposing unsupported distal rectum. Note level II fibers are not shown. U-shaped contour of posterior vaginal wall in level III and W-shaped contour in level II are shown.

DeLancey 1999

Posterior Compartment Methods of Surgical Treatment

- Transvaginal repair (posterior colporrhaphy - site-specific fascial defect repair)
- Transanal repair
- Transperineal repair
- Abdominal repair
- Laparoscopic repair

Posterior Colporrhaphy

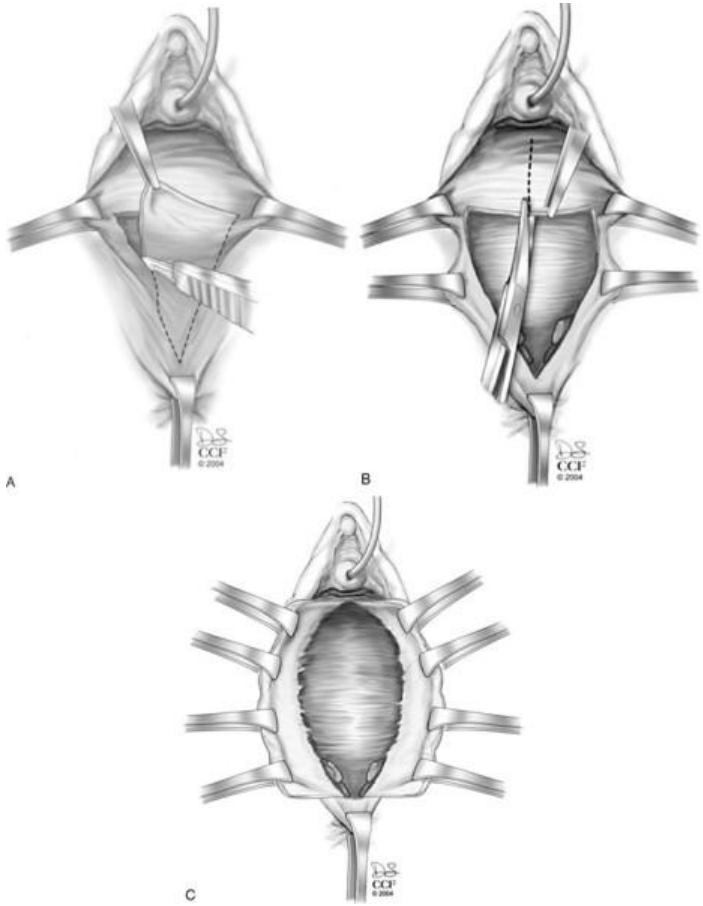

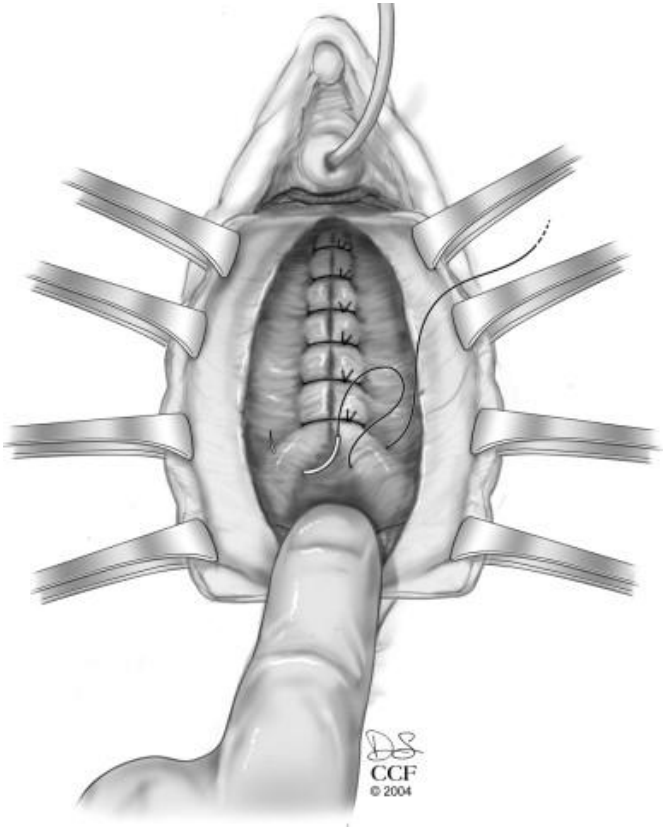

Walters: Urogynecology and Reconstructive Pelvic Surgery, 3rd Ed.

Raz Female Urology, 3rd Ed

Site Specific Repair

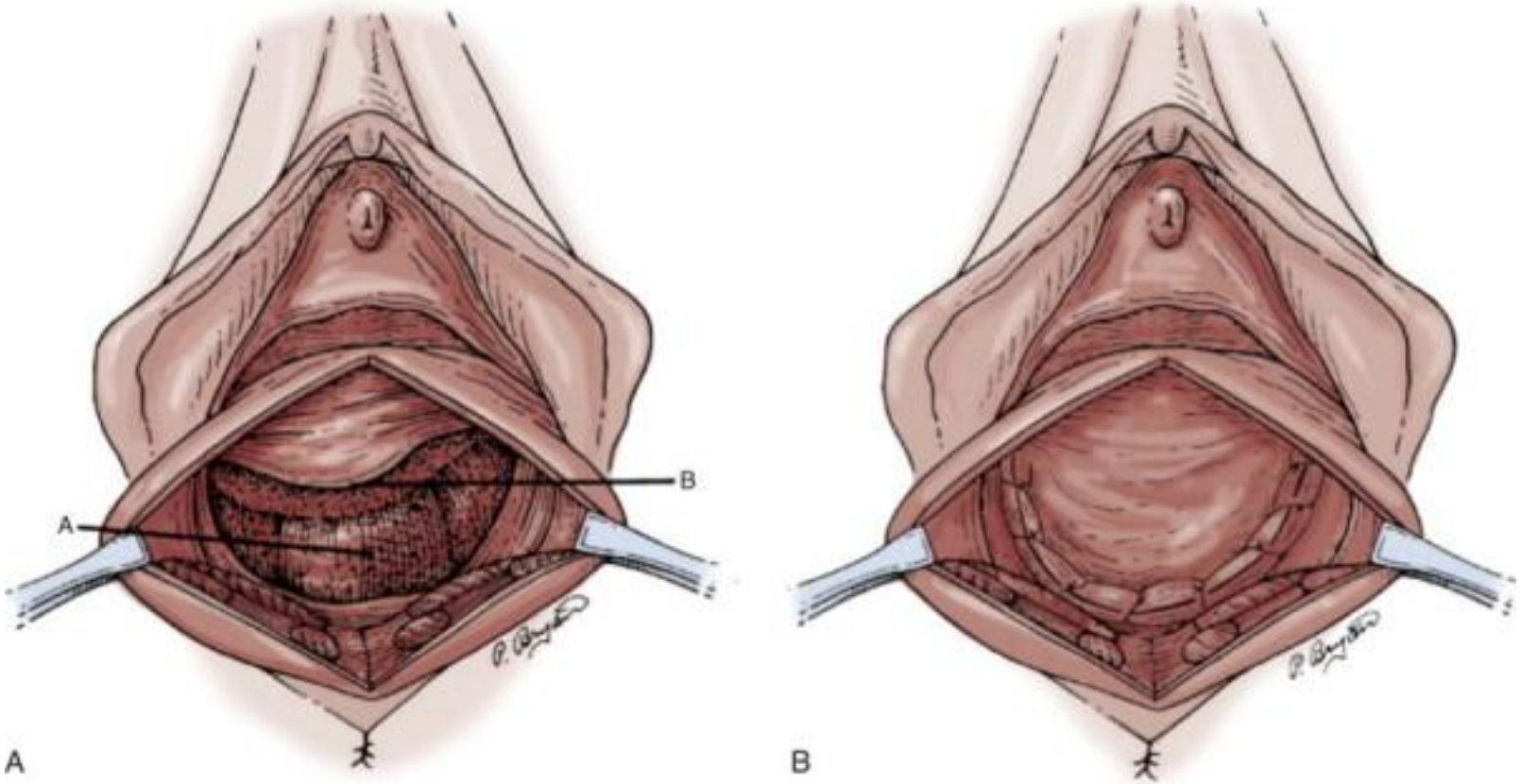

Wein: Campbell-Welsh Urology, 10th Ed

Future Developments

- Anatomical correction of defects
  - Vaginal axis
  - Intermediate section of USL
  - Cardinal ligament
- Regenerative techniques
  - Animal studies
- Restore anatomy and function of deficient anatomical structures

Future Developments 2

- Modern techniques (fine-slice MRI, 3D modeling, biomechanical studies or immunohistochemistry) may improve our knowledge further.
- A better understanding of pelvic organ support may allow the development of novel surgical techniques and result in better outcomes.

Future Developments - 3D Models

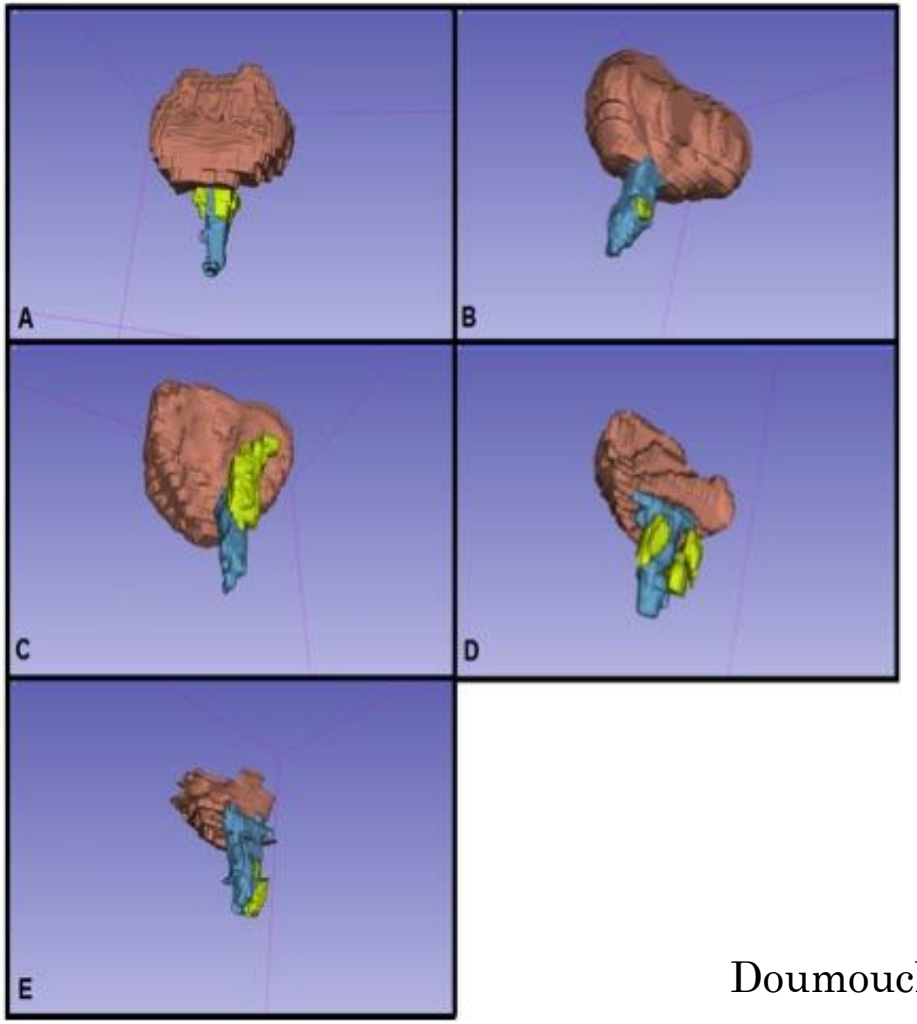

Doumouchtsis et al 2014

Future Developments - 3D Models Visualisation of Deep Structures

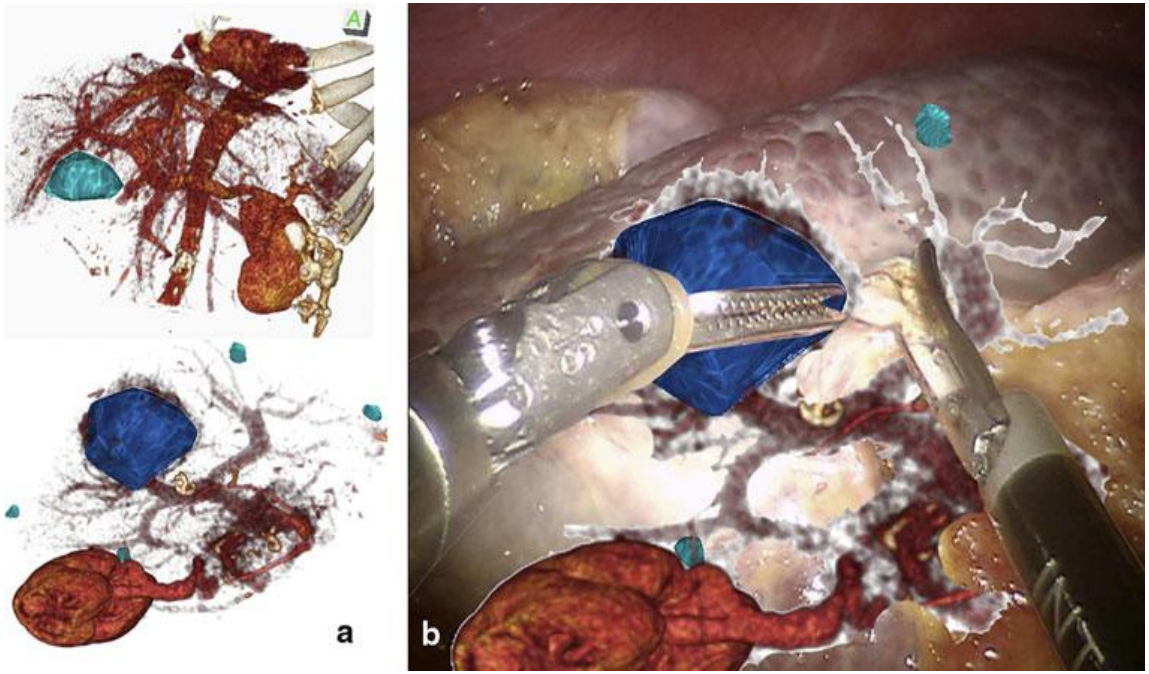

3D volume rendering of hepatic tumour (**dark blue mass**). (**8b**) Fusion of 3D reconstructed images of tumour and stereoscopic view during laparoscopic tumour resection

Volonte 2011

Future Developments - 3D Models Visualisation of Deep Structures

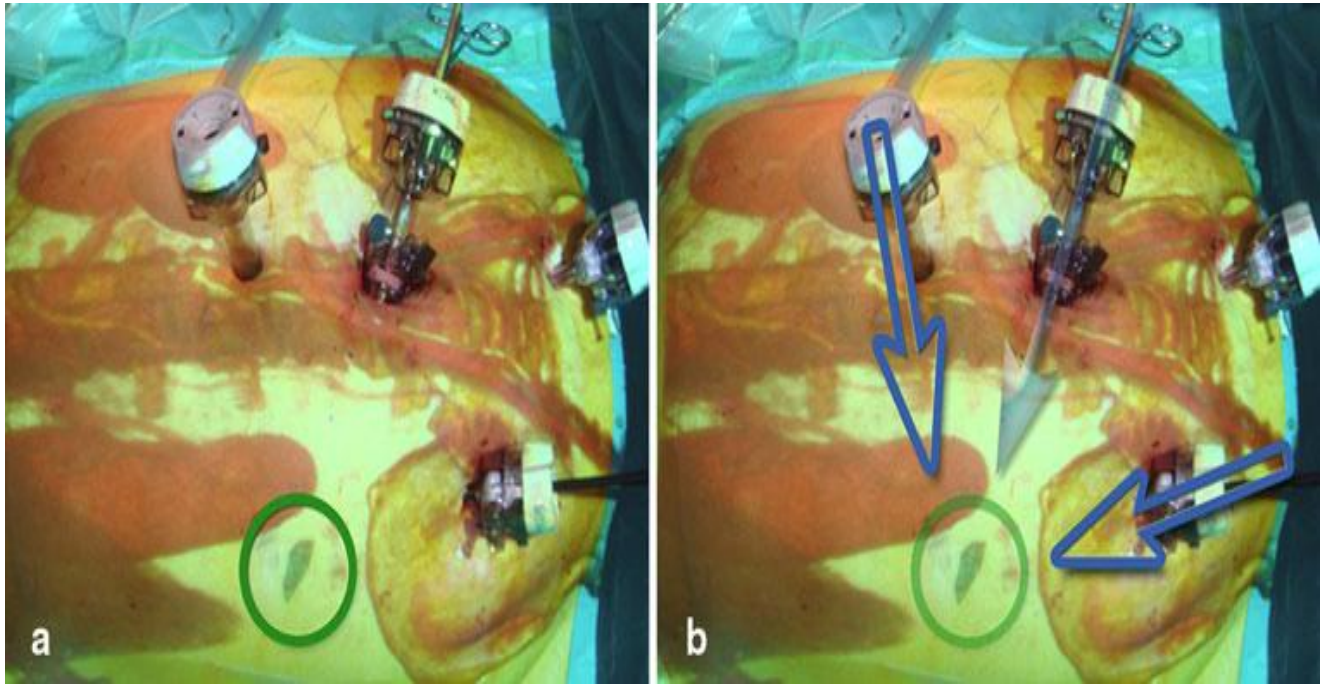

3D Image projection on to the patient allows the exact identification of the mass (**green circle**) and (**9b**) visual triangulation with laparoscopic instruments (**blue arrows**)

Volonte 2011

Thank You